



# CORRELATION OF HISTOPATHOLOGICAL RESULTS AND TOMOGRAPHIC FINDINGS IN PATIENTS WITH LIVER LESIONS SUSPICIOUS FOR MALIGNANCY.

CORRELACIÓN DEL RESULTADO HISTOPATOLÓGICO Y HALLAZGOS TOMOGRÁFICOS EN PACIENTES CON LESIONES HEPÁTICAS SOSPECHOSAS DE MALIGNIDAD.

Luis Pablo Valencia Montiel <sup>1,3a</sup>, Jorge Roberto Hernández Santos <sup>2b</sup>, Arturo García-Galicia <sup>1c</sup>,  
Álvaro José Montiel-Jarquín <sup>1d</sup>, Diana López García <sup>1a</sup>, Maricarmen Tapia Venancio <sup>1a</sup>, Nancy Rosalía Bertado-Ramírez <sup>1f</sup>

## ABSTRACT

**Introduction:** Liver cancer is the seventh most common neoplasm worldwide and the second cause of mortality directly associated with cancer. In Mexico it has an incidence of 3.9% in the entire population. Although computed tomography (CT) is the imaging study of choice, the final diagnosis is established with the anatomopathological study of the lesion. **Objective:** Correlate the tomographic findings with the histopathological result in patients with liver lesions with suspicion of malignancy, who underwent USG-guided biopsy. **Methods:** Descriptive, correlation, retrolective, homodemographic and single-center study. The study period was from September 2021 to February 2022. Patients older than 18 years with liver lesions suspicious of malignancy were selected and underwent Computed Axial Tomography and ultrasound-guided biopsy. Shapiro Wilk tests (for normality) were used and chi-square was used for an analysis of association of categorical variables. **Results:** Twenty-four patients were included, who underwent Tomography and lesion biopsy, finding an average size of lesions of 2.39cm. The results of the correlation between the tomographic diagnosis and the definitive histopathological diagnosis did not have statistical significance  $p=0.069$ . **Conclusion:** No significant correlation was found between the histopathological study and tomographic findings in liver lesions suggestive of malignancy. (sn.)

**Keywords:** Hepatic neoplasms; Biopsy; X-ray computed tomography. (Source: MESH-NLM)

## RESUMEN

**Introducción:** El cáncer hepático es la séptima neoplasia más frecuente a nivel mundial y la segunda causa de mortalidad asociada directamente a cáncer. En México presenta una incidencia del 3.9% en toda la población. A pesar de que la tomografía axial computada es el estudio diagnóstico inicial de elección, el diagnóstico final se establece con el estudio anatomopatológico de la lesión. **Objetivo:** Correlacionar los hallazgos tomográficos con el resultado histopatológico en pacientes con lesiones hepáticas con sospecha de malignidad, a los que se les tomó biopsia dirigida por USG. **Métodos:** Estudio descriptivo, de correlación, retrolectivo, homodémico y unicéntrico. El tiempo de estudio fue de septiembre 2021 a febrero 2022. Se seleccionó a pacientes mayores de 18 años con lesiones hepáticas sospechosas de malignidad, a los que se les realizó tomografía y biopsia guiada por ultrasonido. Se utilizó pruebas de Shapiro-Wilk (de normalidad) y se utilizó  $\chi^2$  para un análisis de asociación de variables categóricas. **Resultados:** Se incluyeron a 24 pacientes, a los cuales se les realizó tomografía y biopsia de lesión, encontrando un tamaño promedio de las lesiones de 2.39cm. Los resultados de la correlación entre el diagnóstico tomográfico y el diagnóstico histopatológico definitivo no tuvieron significancia estadística  $p=0.069$ . **Conclusión:** No se encontró correlación significativa entre el estudio histopatológico y los hallazgos tomográficos en lesiones hepáticas sugerentes de malignidad.

**Palabras clave:** Neoplasias hepáticas; Biopsia; Tomografía computarizada por rayos X. (Fuente: DeCS- BIREME)

<sup>1</sup> Directorate of Education and Research in Health, High Specialty Medical Unit, Hospital de Especialidades de Puebla, Centro Médico Nacional "Gral. de Div. Manuel Ávila Camacho", Instituto Mexicano del Seguro Social, Puebla de Zaragoza, Mexico.

<sup>2</sup> Division of Radiology, High Specialty Medical Unit, Hospital de Especialidades de Puebla, Centro Médico Nacional "Gral. de Div. Manuel Ávila Camacho", Instituto Mexicano del Seguro Social, Puebla de Zaragoza, Mexico.

<sup>3</sup> Faculty of Human Medicine, Universidad Popular Autónoma del Estado de Puebla, Puebla de Zaragoza, Mexico.

<sup>a</sup> General Physician.

<sup>b</sup> Specialist in Radiology.

<sup>c</sup> Specialist in Pediatrics. Master of Medical Sciences and Research.

<sup>d</sup> Specialist in General Surgery. Master of Medical Sciences and Research.

<sup>f</sup> Specialist in Neurology

Cite as: Valencia Montiel LP, Hernández Santos JR, García-Galicia A, Montiel-Jarquín AJ, López García D, Tapia Venancio M, Bertado-Ramírez NR. Correlation of histopathological results and tomographic findings in patients with liver lesions suspicious for malignancy. Rev Fac Med Hum. 2024;24(1):65-72. doi:10.25176/RFMH.v24i1.6012

Journal home page: <http://revistas.urp.edu.pe/index.php/RFMH>

Article published by the Journal of the Faculty of Human Medicine of the Ricardo Palma University. It is an open access article, distributed under the terms of the Creative Commons License: Creative Commons Attribution 4.0 International, CC BY 4.0 (<https://creativecommons.org/licenses/by/4.0/>), which allows non-commercial use, distribution and reproduction in any medium, provided that the original work is duly cited. For commercial use, please contact [revista.medicina@urp.edu.pe](mailto:revista.medicina@urp.edu.pe)





## INTRODUCTION

Liver cancer is the seventh most common neoplasm worldwide. In 2020, the World Health Organization reported an incidence of 4.7% and it's the second leading cause of mortality<sup>(1,2)</sup>. In Latin America and the Caribbean, the incidence is 2.7%. Mexico reports it at 3.9% in the entire population, with a predominance in males at 4.1%<sup>(3)</sup>. The main risk factors include hepatitis B virus infection, hepatitis C virus infection, alcoholism, non-alcoholic fatty liver disease, type 2 diabetes, obesity, and age over 60 years<sup>(6,7)</sup>. Other factors such as systemic arterial hypertension, pancreatitis, sleep apnea, osteoarthritis, liver transplantation, and autoimmune hepatitis are also associated with the development of liver cancer<sup>(8,9)</sup>.

The disease is initially asymptomatic. In the case of hepatocellular carcinoma, early symptoms are associated with liver cirrhosis in over 60% of cases<sup>(10)</sup>. Symptoms in advanced stages include abdominal pain, weight loss, early satiety, palpable mass in the epigastrium, and sometimes paraneoplastic syndromes presenting with hypoglycemia, erythrocytosis, hypercalcemia, diarrhea, and skin conditions<sup>(10)</sup>. On the other hand, cholangiocarcinoma obstructing the biliary drainage may present with abdominal pain (50%), weight loss (40%), fever (20%), jaundice, pruritus, acholia, and stools with a reddish-brown color. The presence of jaundice indicates advanced disease. This is the most aggressive variant of liver cancer<sup>(11,12)</sup>.

Patients at risk for liver cancer are recommended to undergo periodic imaging studies to detect cancerous lesions early. The American, European, and Asian Pacific associations recommend ultrasound, serum tumor markers, and tomography in patients with cirrhosis, hepatitis B, those awaiting liver transplantation, men over 40 years old, and women over 50<sup>(13)</sup>. Suspicion of malignancy in a liver lesion indicates the performance of magnetic resonance imaging, which provides clear images of the tumor and allows classification into intrahepatic or extrahepatic, and the latter into hilar or perihilar<sup>(20)</sup>. Ultrasound (USG) has variable sensitivity and specificity, so in case of doubt or abnormal findings, computed tomography (CT) is performed. Magnetic resonance cholangiopancreatography is performed to define the tumor's location, extent, and other details useful for treatment<sup>(21,22,23)</sup>.

Once the diagnosis of liver cancer is established, it is staged to plan medical and surgical treatment. The classification proposed by the American Joint Committee on Cancer (AJCC) stages liver cancer, and its definitions established in the 8th edition of 2017 are still in use. The AJCC is a TNM classification where T represents the tumor size, N the presence of nodules, and M the existence of metastasis<sup>(24,25)</sup>. The use of CT has been validated by eight associations as the first-choice diagnostic study in suspected liver cancer, as it helps define guidelines for monitoring and medical and surgical treatment<sup>(26,27)</sup>. However, few guidelines condition a sensitivity and specificity between CT findings and histopathological study. Apart from this characteristic, there are no studies exploring the correlation between tomographic findings and histopathological results in patients with liver lesions suspicious of malignancy<sup>(28)</sup>.

## METHODS:

An analytical, correlational study was conducted from 2021 to 2022. It was carried out on patients with liver lesions suspected of malignancy by CT who underwent ultrasound-guided percutaneous biopsy, treated at a tertiary hospital in Puebla, Mexico. Patients over 18 years old with liver lesions suspected of malignancy, who also underwent biopsy of these lesions, were included. Patients who had already received oncological treatment were excluded, and those who requested to leave the study or died during its conduct were eliminated.

A data collection form was used to gather patient information, including variables such as sex, age, risk factors, diagnosis by CT and histopathology, contrast enhancement phase in CT, tumor location by CT, tumor segment affected, tumor size, and the number of days between the imaging study and biopsy. Once patients meeting the inclusion criteria were gathered, it was obtained a convenience sample of 24 patients.

For statistical analysis, frequencies and percentages were calculated, and measures of central tendency including mean, median, and mode, as well as measures of dispersion consisting of minimum, maximum, and standard deviation, were used.





Shapiro-Wilk tests were used for normality, obtaining a normal distribution ( $p > 0.5$ ). 2 tests were used for an analysis of association of categorical variables, obtaining  $p > 0.05$ . A database was created in the IBM SPSS Statistics pack version 25 statistical processor, and all variables and their results were entered in numerical language. The protocol was approved by the Local Health Research Committee. Patient anonymity was preserved at all times, and the data were used solely for scientific purposes.

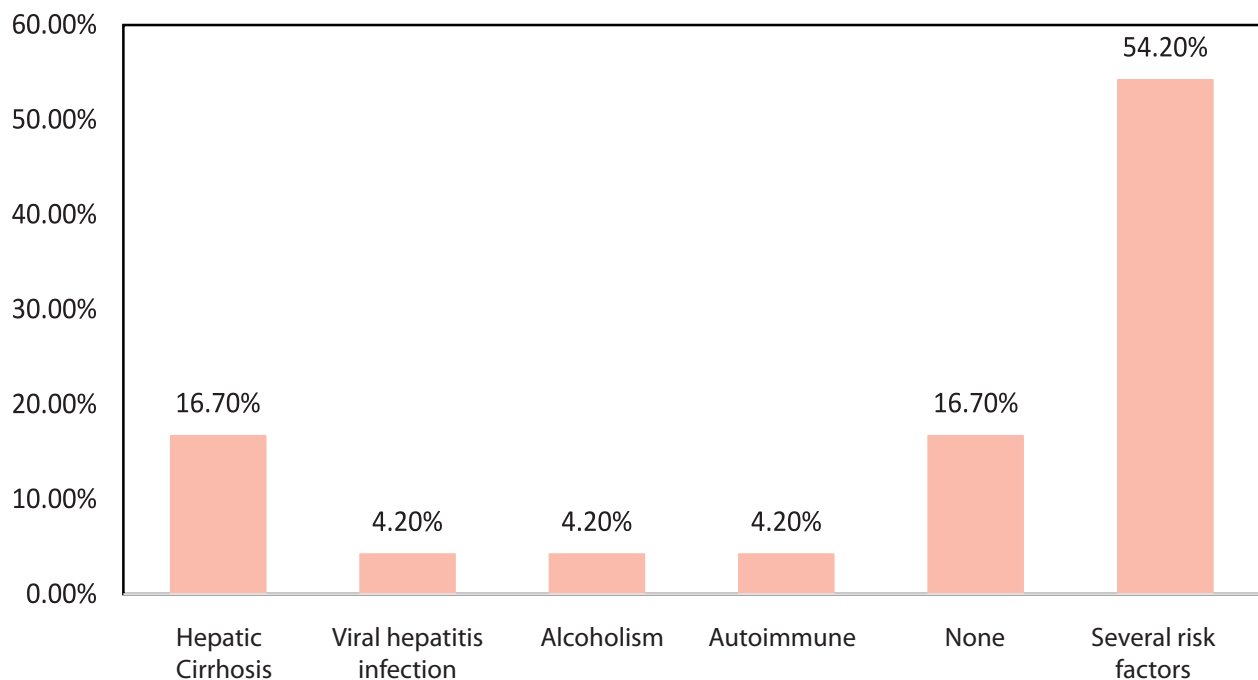
## RESULTS

Out of a total population of 24 patients, it was found

that 10 (41.70%) were men and 14 (58.3%) were women, with a mean age of 57.54 years. The mean number of days between the performance of both studies was 23.50 days with a standard deviation of 12.56 days. The elapsed time ranged from 2 to a maximum of 50 days. The average lesion size was 2.39cm as determined by both tomography and biopsy.

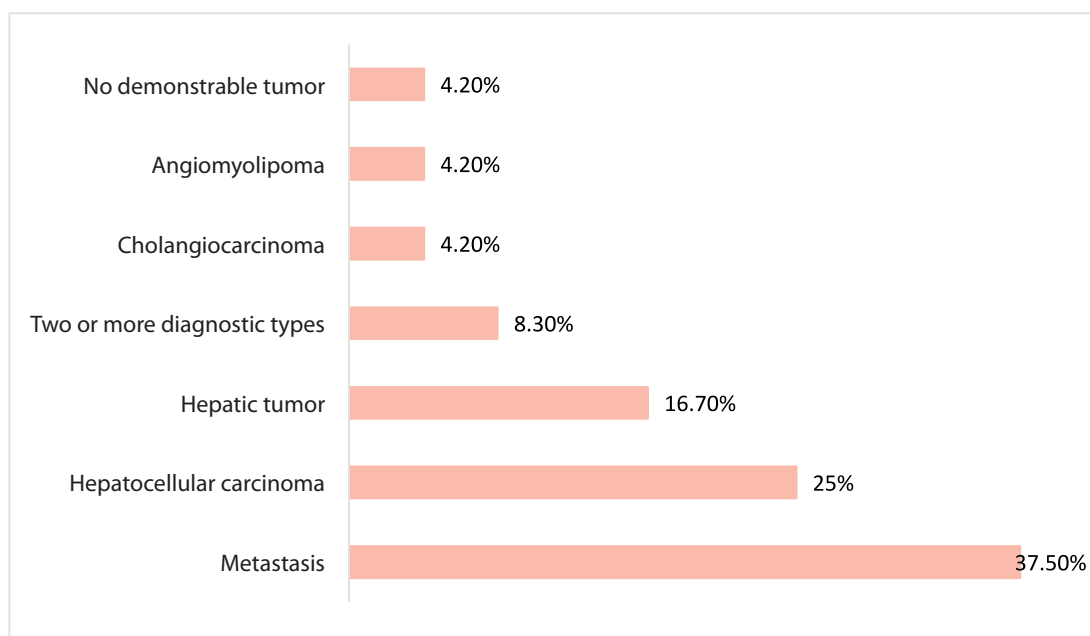
The presence of comorbidities in the sample population included hepatic cirrhosis, with a prevalence of 16.70%. However, the majority of patients had one or more comorbidities, resulting in a prevalence of 54.20%.

**Graph 1.** Comorbidities associated with liver cancer.



The most frequent tomographic diagnosis was metastasis, with  $n=9$  (37.50%), followed by hepatocellular carcinoma with 6 (25%),

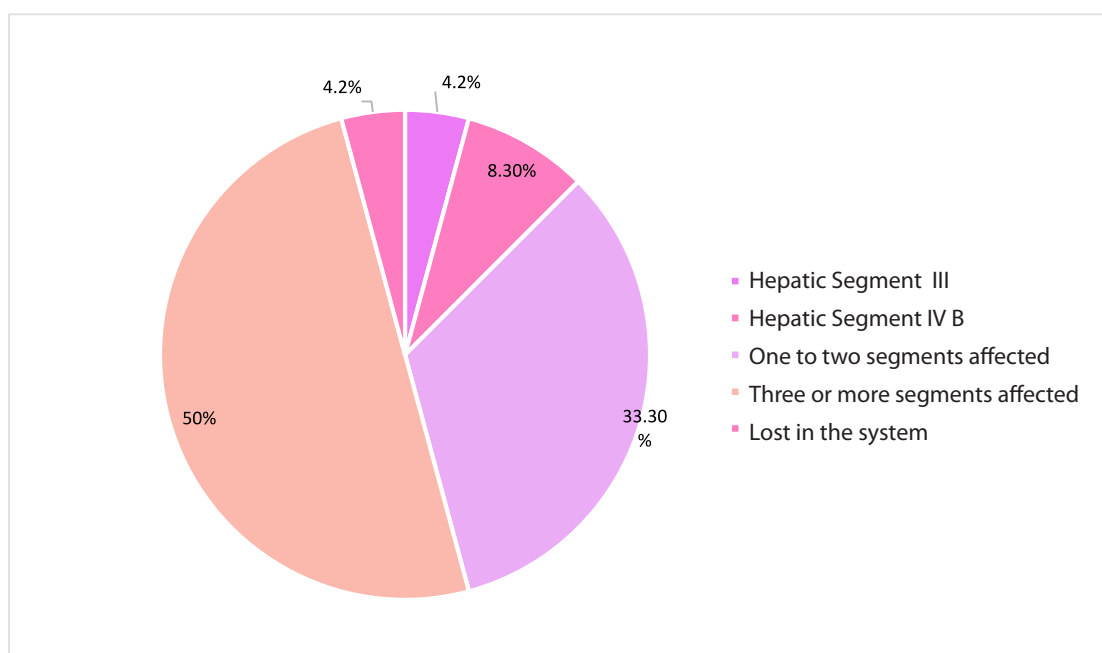
and in third place, hepatic tumor with 4 (16.70%). The rest of the diagnoses are shown in Figure 2.

**Graph 2.** Tomographic diagnoses.

ORIGINAL PAPER

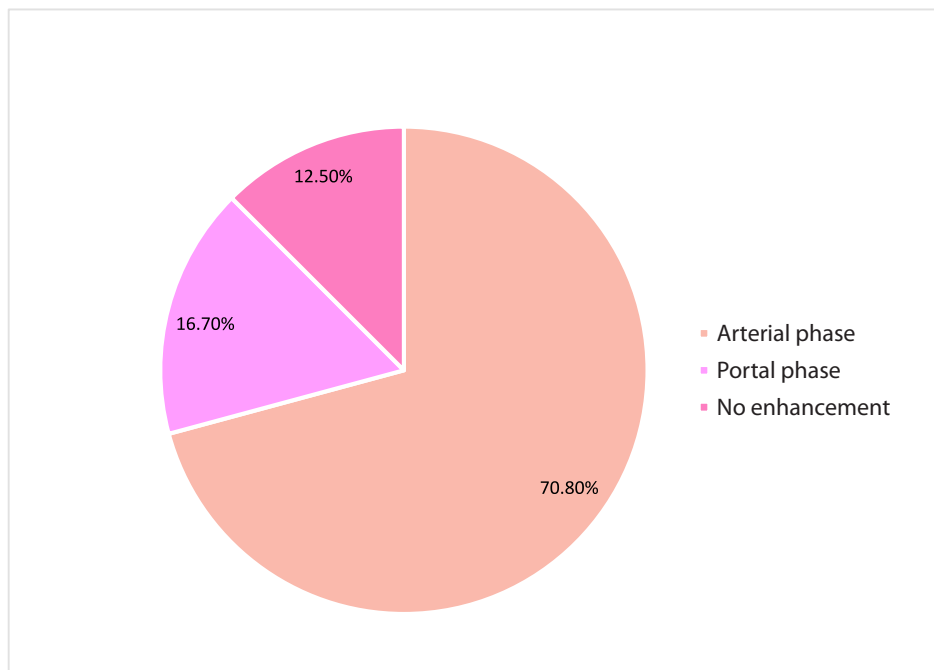
Regarding the hepatic segments, most patients had three or more liver segments affected by the tumor, 12 (50%). Only one patient had no affected segments because the presence of the tumor could not be

demonstrated by CT scan, and the phase with the most enhancement due to the tumor was the arterial phase, 17 (70.80%) (See Figures 3 and 4).

**Graph 3.** Affected hepatic segments.



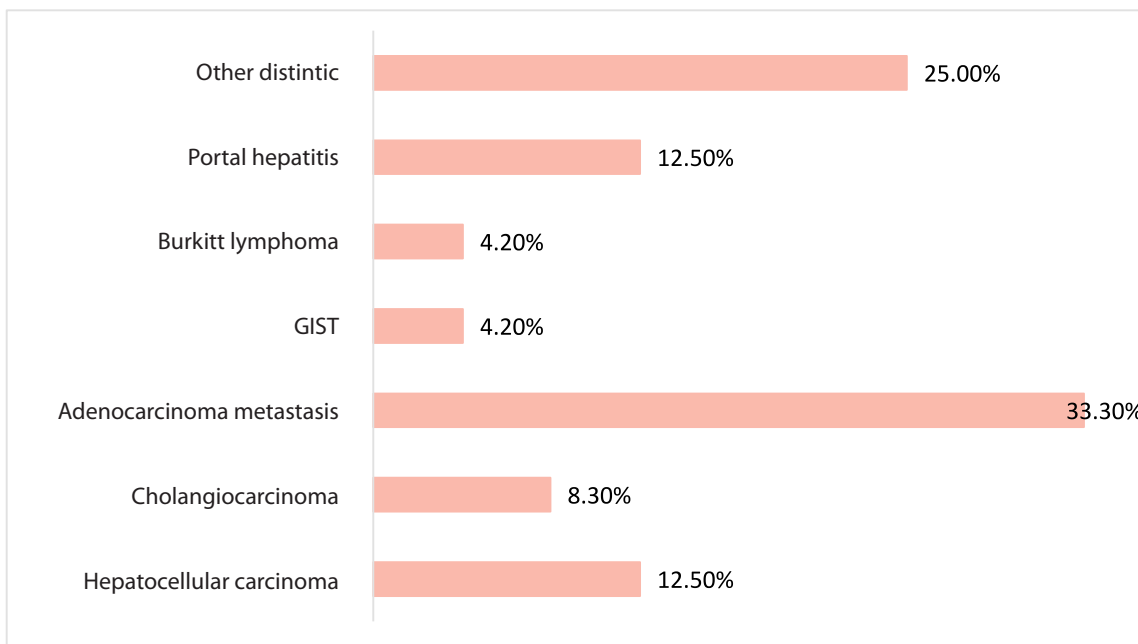
**Graph 4.** Enhancement phase of tumor.



Out of the 24 patients with liver lesions, 15 (62.50%) tested positive for malignancy, while 9 (37.50%) had a negative result for malignancy.

The primary histopathological diagnosis was adenocarcinoma metastasis, accounting for 8 (33.30%) cases. The remaining diagnoses are shown below.

**Graph 5.** Histopathological result.



The results of the correlation between the tomographic diagnosis and the definitive histopathological diagnosis did not show statistical significance ( $p=0.10$ ), and the correlation coefficient was 0.61, indicating a weak correlation.



## DISCUSSION

Despite CT scanning being ideal for diagnosing liver cancer, it is necessary to distinguish the characteristics of a primary tumor and a metastasis site regardless of the patient's clinical presentation. Various studies have been conducted to distinguish between them, concluding that a primary tumor is more frequently established in liver segment 8, while metastases are expressed in segment 5<sup>(29,30)</sup>. For lesions larger than 2 cm, CT is considered the gold standard for detecting malignant liver neoplasms with diagnostic accuracy of almost 100%. However, its sensitivity decreases to approximately 60% when the lesion is smaller<sup>(31)</sup>.

A total of 24 patients with suspected malignant liver lesions were analyzed over a six-month period, with a mean age of 57.54 years, mostly female. This is in line with international guidelines for liver and biliary tract cancer, which show increased predisposition in women after 50 years of age, although it differs from other descriptive studies where nearly 60% of the population are men<sup>(22,32,33)</sup>. On the other hand, the majority of the included population had a variety of comorbidities; however, when analyzed in isolation, the presence of liver cirrhosis was the most predominant characteristic, with an estimated 80% of patients worldwide with a history of or current hepatocellular carcinoma having this antecedent<sup>(34)</sup>.

Another comorbidity reported as a fundamental cause of liver cancer is prior infection with Hepatitis B and C viruses, which for a long time was considered the main triggering factor for this neoplasm; however, in this population, the percentages reached 4.20% of the total sample included<sup>(35,36)</sup>. Regarding imaging studies, the primary imaging method used is ultrasound due to its low cost; however, the sensitivity and specificity it offers are lower than other imaging techniques such as CT scan. Nonetheless, due to its clear difficulty in lesions <1cm, it is suggested that a biopsy of the lesion be performed to confirm the findings, as was done in this study<sup>(37)</sup>.

Similarly, concerning the characteristics obtained by imaging, hepatocellular carcinoma can be diagnosed, for example, if the main finding on the CT scan is enhancement in the hepatic arterial phase combined with washout in the portal phase, confirming the presence of a neoplastic lesion. However, in this study, only 12.5% of the population had this characteristic, while more than 60% did not show enhancement, so it was necessary to perform a liver biopsy in all patients for confirmation<sup>(37)</sup>. Regarding liver segments, most patients had more than one segment affected by the lesion, this being due to the average lesion size of 2.39 centimeters, while the maximum tumor size found in patients in this study was 3 centimeters.

On the other hand, concerning histopathological study, the main types of neoplastic lesions diagnosed are cholangiocarcinoma and hepatocellular carcinoma, with the latter being the most common of the two<sup>(38)</sup>. When correlating the findings obtained by computed tomography and by histopathology in suspicious liver lesions, it was found that the main diagnosis given by these two tools was hepatocellular carcinoma (25%); on the other hand, regarding cholangiocarcinoma visualized by CT scan, it was only demonstrated in 4.2% of the population, which differs considerably from the biopsy, which was demonstrated in 8.3%.

Placing the results in the contingency table for diagnostic test evaluation, computed tomography was taken into consideration at the top of the table, and the anatomopathological study obtained by ultrasound-guided biopsy, in which each column represented cases positive for malignancy obtained in both studies, and each row represented the suspicion of malignancy. Additionally, the diagnostic possibilities of both auxiliary techniques in the diagnosis of neoplastic pathologies were not the same, and there was no significant difference between the diagnostic suspicion provided by the imaging study, in this case, the CT scan, and the confirmation study, which is the biopsy for subsequent pathological anatomy study.





Among the limitations of the study is that the sample size is smaller compared to previous studies; however, this limitation did not prevent the study objectives from being met.

**Authorship Contribution:** The authors participated in the genesis of the idea, project design, data collection and interpretation, results analysis, and manuscript preparation of the present research work.

**Funding:** The authors received no assistance or funding for the present work.

**Correspondence:** Álvaro José Montiel-Jarquín.

**Address:** Calle 2 norte # 2004. Colonia Centro. CP 72000. Puebla, Pue.

**Telephone:** +52 (222) 2424520 extensión 61315. **Teléfono móvil:** +521 2222384907

**Email:** [dralmoja@hotmail.com](mailto:dralmoja@hotmail.com)

## CONCLUSION

There was no significant correlation between histopathological study and tomographic findings in suspected malignant liver lesions.

**Conflict of Interest:** The authors declare no conflict of interest.

**Received:** October 24, 2023.

**Accepted:** April 08, 2024.

## REFERENCES

- McGlynn KA, Petrick JL, El-Serag HB. Epidemiology of Hepatocellular Carcinoma. *Hepatology* [Internet]. 2021 Jan 24;73(S1):4–13. Available from: <https://onlinelibrary.wiley.com/doi/10.1002/hep.31288>
- World Health Organization. Top cancer per country, estimated number of new cases in 2020 [Internet]. Global Cancer Observatory. 2020. Available from: [https://gco.iarc.fr/today/online-analysis-map?v=2020&mode=cancer&mode\\_population=continents&population=900&populations=900&key=total&sex=0&cancer=39&type=0&statistic=5&prevalence=0&population\\_group=0&ages\\_group%5B%5D=0&ages\\_group%5B%5D=17&nb\\_items=10&group](https://gco.iarc.fr/today/online-analysis-map?v=2020&mode=cancer&mode_population=continents&population=900&populations=900&key=total&sex=0&cancer=39&type=0&statistic=5&prevalence=0&population_group=0&ages_group%5B%5D=0&ages_group%5B%5D=17&nb_items=10&group)
- World Health Organization. Estimated number of new cases [Internet]. Global Cancer Observatory. 2020. Available from: [https://gco.iarc.fr/today/online-analysispie?v=2020&mode=cancer&mode\\_population=continents&population=900&populations=484&key=total&sex=2&cancer=39&type=0&statistic=5&prevalence=0&population\\_group=0&ages\\_group%5B%5D=0&ages\\_group%5B%5D=17&nb\\_items=10&group](https://gco.iarc.fr/today/online-analysispie?v=2020&mode=cancer&mode_population=continents&population=900&populations=484&key=total&sex=2&cancer=39&type=0&statistic=5&prevalence=0&population_group=0&ages_group%5B%5D=0&ages_group%5B%5D=17&nb_items=10&group)
- An L, Zeng HM, Zheng RS, Zhang SW, Sun KX, Zou XN, et al. Liver cancer epidemiology in China, 2015. *Zhonghua Zhong Liu Za Zhi*. 2019;41(10):721–7.
- World Health Organization. Estimated number of deaths in 202 [Internet]. Global Cancer Observatory. 2020. Available from: [https://gco.iarc.fr/today/online-analysispie?v=2020&mode=cancer&mode\\_population=continents&population=900&populations=484&key=total&sex=2&cancer=39&type=1&statistic=5&prevalence=0&population\\_group=0&ages\\_group%5B%5D=0&ages\\_group%5B%5D=17&nb\\_items=7&group](https://gco.iarc.fr/today/online-analysispie?v=2020&mode=cancer&mode_population=continents&population=900&populations=484&key=total&sex=2&cancer=39&type=1&statistic=5&prevalence=0&population_group=0&ages_group%5B%5D=0&ages_group%5B%5D=17&nb_items=7&group)
- Yang WS, Zeng XF, Liu ZN, Zhao QH, Tan YT, Gao J, et al. Diet and liver cancer risk: A narrative review of epidemiological evidence. *Br J Nutr*. 2020;124(3):330–40.
- Hochstetler C, McMillian N, Schonfeld R. Hepatobiliary Cancers. *Natl Compr Cancer Netw* [Internet]. 2022 Sep;1. Available from: <https://nccn.org/view/journals/inccn/4/8/article-p728.xml>
- Sohn W, Lee HW, Lee S, Lim JH, Lee MW, Park CH, et al. Obesity and the risk of primary liver cancer: A system-atic review and meta-analysis. *Clin Mol Hepatol*. 2020;27(1):157–74.
- Pauff SM, Miller SC. NIH Public Access. *JAMA* [Internet]. 2011;17. Available from: <https://www.ncbi.nlm.nih.gov/pmc/articles/PMC3624763/pdf/nihms412728.pdf>
- Schwartz J, Carithers R, Sirlin C. Clinical features and diagnosis of retinoblastoma. *UpToDate*. 2021.
- Lowe RC, Anderson C, Kowdley K. Clinical manifestations and diagnosis of cholangiocarcinoma. *Author. UpToDate*. 2020.
- Banales JM, Marin JJG, Lamarca A, Rodrigues PM, Khan SA, Roberts LR, et al. Cholangiocarcinoma 2020: the next horizon in mechanisms and management. *Nat Rev Gastroenterol Hepatol* [Internet]. 2020 Sep 30;17(9):557–88. Available from: <http://dx.doi.org/10.1038/s41575-020-0310-z>
- Yang JD, Heimbach JK. New advances in the diagnosis and management of hepatocellular carcinoma. *BMJ* [Internet]. 2020 Oct 26; Available from: <https://www.bmj.com/lookup/doi/10.1136/bmj.m3544>
- Villanueva A. Hepatocellular Carcinoma. Longo DL, editor. *N Engl J Med* [Internet]. 2019 Apr 11;380(15):1450–62. Available from: <https://onlinelibrary.wiley.com/doi/10.1002/hep.510280436>
- Maennich D, Marshall L. Hepatocellular carcinoma. *Nat Rev Dis Prim* [Internet]. 2021 Dec 21;7(1):7. Available from: <http://www.nature.com/articles/s41572-021-00245-6>
- Llovet JM, Kelley RK, Villanueva A, Singal AG, Pikarsky E, Roayaie S, et al. Hepatocellular carcinoma. *Nat Rev Dis Prim* [Internet]. 2021 Dec 21;7(1):6. Available from: <http://dx.doi.org/10.1038/s41572-020-00240-3>
- Piñero F, Dirschwolf M, Pessôa MG. Biomarkers in Hepatocellular Carcinoma: Diagnosis, Prognosis and Treatment Response Assessment. *Cells* [Internet]. 2020 Jun 1;9(6):1370. Available from: <https://www.mdpi.com/2073-4409/9/6/1370>
- Buckholz AP, Brown RS. Cholangiocarcinoma Diagnosis and Management. *Clin Liver Dis* [Internet]. 2020 Aug;24(3):421–36. Available from: <https://linkinghub.elsevier.com/retrieve/pii/S1089326120300301>
- Forner A, Vidili G, Rengo M, Bujanda L, Ponz-Sarvisé M, Lamarca A. Clinical presentation, diagnosis and staging of cholangiocarcinoma. *Liver Int* [Internet]. 2019 May 25;39(S1):98–107. Available from: <https://onlinelibrary.wiley.com/doi/10.1111/liv.14086>
- Goeppert B. Cholangiokarzinome – Übersicht zur aktuellen anatomischen, histomorphologischen und morphomolekularen Klassifikation. *Pathologe* [Internet]. 2020 Sep 5;41(5):488–94. Available from: <https://link.springer.com/10.1007/s00292-020-00808-6>
- Dondossola D, Ghidini M, Grossi F, Rossi G, Foschi D. Practical review for diagnosis and clinical management of perihilar cholangiocarcinoma. *World J Gastroenterol* [Internet]. 2020 Jul 7;26(25):3542–61. Available from: <https://www.wjnet.com/1007-9327/full/v26/i25/3542.htm>
- National Comprehensive Cancer Network. Hepatobiliary cancers. *NCCN Clin Pract Guidel Oncol*. 2022;1.
- Zarębska I, Gzil A, Dursiewicz J, Jaworski D, Antosik P, Ahmadi N, et al. The clinical, prognostic and therapeutic significance of liver cancer stem cells and their markers [Internet]. Vol. 45, *Clinics and Research in Hepatology and Gastroenterology*. 2021. p. 101664. Available from: <https://linkinghub.elsevier.com/retrieve/pii/S2210740121000437>
- Rastogi A. Changing role of histopathology in the diagnosis and management of hepatocellular carcinoma. *World J Gastroenterol* [Internet]. 2018 Sep 21;24(35):4000–13. Available from: <http://www.wjnet.com/1007-9327/full/v24/i35/4000.htm>



25. Karadag Soyulu N. Update on Hepatocellular Carcinoma: a Brief Review from Pathologist Standpoint. *J Gastrointest Cancer* [Internet]. 2020 Dec 26;51(4):1176–86. Available from: <https://link.springer.com/10.1007/s12029-020-00499-5>
26. Di Tommaso L, Spadaccini M, Donadon M, Personeni N, Elamin A, Aghemo A, et al. Role of liver biopsy in hepatocellular carcinoma. *World J Gastroenterol*. 2019;25(40):6041–52.
27. Xu X, Zhang HL, Liu QP, Sun SW, Zhang J, Zhu FP, et al. Radiomic analysis of contrast-enhanced CT predicts microvascular invasion and outcome in hepatocellular carcinoma. *J Hepatol* [Internet]. 2019;70(6):1133–44. Available from: <https://doi.org/10.1016/j.jhep.2019.02.023>
28. Krishan A, Mittal D. Ensembled liver cancer detection and classification using CT images. *Proc Inst Mech Eng Part H J Eng Med* [Internet]. 2021;235(2):232–44. Available from: <https://doi.org/10.1177/0954411920971888>
29. Wang X, Liu L, Ma N, Zhao X. Computed Tomography Image Feature under Intelligent Algorithms in Diagnosing the Effect of Humanized Nursing on Neuroendocrine Hormones in Patients with Primary Liver Cancer. Rajakani K, editor. *J Healthc Eng* [Internet]. 2021 Oct 6;2021:1–11. Available from: <https://www.hindawi.com/journals/jhe/2021/4563100/>
30. Kim TH, Kim SY, Tang A, Lee JM. Comparison of international guidelines for noninvasive diagnosis of hepatocellular carcinoma: 2018 update. *Clin Mol Hepatol*. 2019;25(3):245–63.
31. Kircher A, Bongartz G, Merkle EM, Zech CJ. Rationale Schnittbildgebung des hepatozellulären Karzinoms. *Radiologe* [Internet]. 2014 Jul 12;54(7):664–72. Available from: <http://link.springer.com/10.1007/s00117-014-2652-4>.
32. Larbi A, Orliac C, Frandon J, Pereira F, Ruyer A, Goupil J, et al. Detection and characterization of focal liver lesions with ultra-low dose computed tomography in neoplastic patients. *Diagn Interv Imaging* [Internet]. 2018 May;99(5):311–20. Available from: <https://linkinghub.elsevier.com/retrieve/pii/S2211568417302838>
33. Cathomas M, Mertineit N, Kim-Fuchs C, Lachenmayer A, Maurer MH. Value of MRI/CT Image Fusion for Targeting “invisible” Lesions in Stereotactic Microwave Ablation (SMWA) of Malignant Liver Lesions: A Retrospective Analysis. *Cardiovasc Intervent Radiol* [Internet]. 2020 Oct 8;43(10):1505–14. Available from: <https://link.springer.com/10.1007/s00270-020-02565-8>
34. Nakamura Y, Higaki T, Honda Y, Tatsugami F, Tani C, Fukumoto W, et al. Advanced CT techniques for assessing hepatocellular carcinoma. *Radiol Med* [Internet]. 2021 Jul 5;126(7):925–35. Available from: <https://link.springer.com/10.1007/s11547-021-01366-4>
35. Yang JD, Hainaut P, Gores GJ, Amadou A, Plymoth A, Roberts LR. A global view of hepatocellular carcinoma: trends, risk, prevention and management. *Nat Rev Gastroenterol Hepatol* [Internet]. 2019 Oct 22;16(10):589–604. Available from: <https://www.nature.com/articles/s41575-019-0186-y>
36. Huang DQ, El-Serag HB, Loomba R. Global epidemiology of NAFLD-related HCC: trends, predictions, risk factors and prevention. *Nat Rev Gastroenterol Hepatol* [Internet]. 2021 Apr 21;18(4):223–38. Available from: <http://www.nature.com/articles/s41575-020-00381-6>
37. Jiang H-Y, Chen J, Xia C-C, Cao L-K, Duan T, Song B. Noninvasive imaging of hepatocellular carcinoma: From diagnosis to prognosis. *World J Gastroenterol* [Internet]. 2018 Jun 14;24(22):2348–62. Available from: <http://www.wjgnet.com/1007-9327/full/v24/i22/2348.htm>
38. Mejia JC, Pasko J. Primary Liver Cancers. *Surg Clin North Am* [Internet]. 2020 Jun;100(3):535–49. Available from: <https://linkinghub.elsevier.com/retrieve/pii/S0039610920300268>