



SACROILIAC ARTHROMYELITIS: CASE REPORT

ARTROMIELITIS SACROILIACA: REPORTE DE CASO

Roger Antonio Sernaque Mechato ^{1a}, Pablo Alberto Romero Sánchez ^{2b}, Julio Andrés Mamani Murillo ^{2b}, Yelenit Emily Quiñones Rodríguez ^{2b}, Marco André Moncada Solano ^{2b}, Jesús Darío Toledo de la Torre ^{3b}

ABSTRACT

Introduction: Infectious sacroiliitis is a rare condition that is sometimes diagnosed late due to the poor specificity of the symptoms. In addition, imaging techniques such as scintigraphy, tomography, and nuclear magnetic resonance are required to assess the extent and severity of the lesions. If early diagnosis and treatment are made, the clinical evolution is satisfactory and leaves no sequelae. **Clinical case:** the case of an 83-year-old female patient is presented, with a history of ischemic cerebrovascular disease, high blood pressure, type 2 diabetes mellitus and urinary tract infection, who presented with moderately intense colic-like abdominal pain, afebrile, and reported that at the time After getting up from his chair he felt weakness in his left side. On admission, hypertensive, febrile with T°: 38°C SatO₂: 98% with FiO₂: 0.4. On physical examination, there was edema in MMII with pitting (+), distended abdomen, pain in the right flank and left hemiparesis. To the laboratory: hemoglobin 14.8 g/dl, platelets 38,000 µl, leukocytes 18,000 µl. Subsequently, confirming the clinical diagnosis supported by radio images, the surgical approach was performed. **Conclusion:** IBS is a rare disease with serious complications, whose early diagnosis and rapid initiation of treatment are essential, based mainly on the clinical picture, imaging studies and the appropriate duration of antibiotic therapy.

Keywords: Septic arthritis; Septic sacroileitis. (Source: MESH-NLM)

RESUMEN

Introducción: La sacroileítis infecciosa (SII) es una afección poco común que, en ocasiones, se diagnostica tarde por la escasa especificidad de los síntomas. Además, se requiere de técnicas de imagen como la gammagrafía, tomografía y la resonancia magnética nuclear para valorar la extensión y gravedad de las lesiones. Si se hace un diagnóstico y tratamiento precoz, la evolución clínica es satisfactoria y no deja secuelas. **Caso clínico:** Se presenta el caso de una paciente mujer de 83 años, con antecedentes de enfermedad cerebrovascular isquémico, hipertensión arterial, diabetes mellitus 2 e infección del tracto urinario que presentó dolor abdominal tipo cólico de moderada intensidad, afebril; manifestó que al momento de levantarse de su silla sintió debilidad en el hemicuerpo izquierdo. Al ingreso, hipertensa, febril con T° 38°C SatO₂: 98 % con FiO₂: 0.4. Al examen físico con edema en MMII con fóvea (+), abdomen distendido, doloroso en flanco derecho y hemiparesia izquierda. Al laboratorio: hemoglobina 14,8 g/dl, plaquetas 38.000 µl. leucocitos 18.000 µl. Posteriormente, confirmando el diagnóstico clínico sustentado en radio imágenes, se procedió al abordaje quirúrgico. **Conclusión:** La SII es una enfermedad rara con complicaciones graves, cuyo diagnóstico precoz e inicio de tratamiento rápido son fundamentales, basándose principalmente en el cuadro clínico, estudios de imágenes y la duración adecuada de la terapia antibiótica.

Palabras clave: Artritis séptica; Sacroileítis séptica. (Fuente: DeCS- BIREME)

¹ Hospital Santa Rosa. Lima, Perú.

² Instituto de investigaciones en Ciencias Biomédicas de la Universidad Ricardo Palma. Lima, Perú.

³ Universidad Federico Villarreal.

^a Internist physician.

^b Human Medicine Intern.

Cite as: Sernaque Mechato RA, Romero Sánchez PA, Mamani Murillo JA, Quiñones Rodríguez YE, Moncada Solano MA, Toledo de la Torre JD. Sacroiliac Arthromyelitis: Case Report. Rev Fac Med Hum. 2023;23(4):158-162. doi 10.25176/RFMH.v23i4.6110

Journal home page: <http://revistas.urp.edu.pe/index.php/RFMH>

Article published by the Journal of the Faculty of Human Medicine of the Ricardo Palma University. It is an open access article, distributed under the terms of the Creative Commons License: Creative Commons Attribution 4.0 International, CC BY 4.0 (<https://creativecommons.org/licenses/by/4.0/>), which allows non-commercial use, distribution and reproduction in any medium, provided that the original work is duly cited. For commercial use, please contact revista.medicina@urp.edu.pe





INTRODUCTION

Infectious sacroiliitis (ISI) was first described by Poore in 1878, and since then the literature on this infection has mainly come from case reports and small series of patients⁽¹⁾. The incidence of ISI is relatively low, approx. 1%. It represents 2% of all cases.

A case of septic arthritis^(2,3). This can be due to several different reasons, causes including degenerative diseases, trauma, pregnancy, intravenous drug use, immunosuppressive therapy, hemoglobin disorders, inflammatory diseases and infections such as endocarditis and urinary tract or dermatitis; however, these risk factors may only be present in patients in 55% to 60% of identified cases⁽¹⁾. Unilateral sacroiliitis should guide the diagnosis of ISI⁽⁴⁾, although unilateral sacroiliitis is associated with spondyloarthropathies (psoriatic arthritis, early, reactive ankylosing spondylitis), which represents a diagnostic challenge.

Contamination can be the product of bacteremia due to a contiguous infection or direct inoculation, as in the case of joint infiltrations⁽⁷⁾. Infections can be caused by pyogenic organisms and tuberculosis⁽⁵⁻⁸⁾.

Nonspecific initial symptoms and variable physical examination findings make diagnosis difficult and are often missed from the outset. The clinical manifestations are different, but the most common pain is in the lower back and buttocks, which worsens when walking. Magnetic resonance imaging (MRI) of the pelvis is the gold standard for diagnosing ISI⁽⁶⁾. Long-term antibiotic treatment, lasting more than four weeks, is considered adequate treatment⁽⁹⁾.

CLINICAL CASE

The case of an 83-year-old female patient with a medical record of cerebrovascular disease, high blood pressure, type 2 diabetes mellitus, and urinary tract infection is presented. The patient suddenly presented, two days before admission, moderately intense colic-like pain in the right flank, weakness of the left side of the body, dysarthria, and intermittent febrile symptoms. During the physical examination on admission, regarding vital signs, it was found: BP: 140/70, T: 38.2°. Regarding the skin and pharynx, edema

of the lower limbs and fovea was evident (+). At the respiratory level, the vesicular murmur was decreased in both lung fields. Regarding the CV system, a holosystolic murmur was heard. Furthermore, regarding the abdomen, there was pain on palpation in the hypogastrium and regarding the CNS, there was left hemiparesis.

Regarding the somatic physical examination, a flexion, abduction, and external rotation test (FABERE) was performed, positive, Gaenslen-Mennel test, positive; Log Roll test of the left hip, negative; negative signs of root irritation without palpable inguinal lymphadenopathy. Laboratory tests revealed: basal glucose 537, urea 170, leukocytosis 18,000, plateletopenia 38,000, fed 3%, segmented 80%, lymphocytes 10%, prothrombin T 17.3. In addition, there was a pathological urine test (proteins 2+, nitrites +, blood +, leukocytes +; regarding urinary sediment: red blood cells at 139.92/uL. and white blood cells at 640.20/uL).

A brain Tomography without contrast was performed, which showed tomographic signs in relation to right fronto-parieto-temporal subacute ischemic stroke, dependent on the territory of the right MCA. Likewise, an EKG was performed with a diagnosis of atrial fibrillation with controlled ventricular response and a complete abdominal ultrasound with a diagnosis of left kidney stones and grade II hydronephrosis. Due to the persistence of intermittent febrile symptoms with a focus to be determined, serial control laboratory tests were performed after seven days, which revealed basal glucose of 221 mg/dL, urea of 211 mg/dL, CRP of 23.28, and creatinine of 3.30 mg./dL, leukocytes 13,380 xmm³, platelets 42,000, 4% segmented, 88% segmented and 6% lymphocytes.

Due to the remarkable symptoms, probable physical examination tests and ultrasound examinations with unilluminating results, it was decided to perform a Tomography of the abdomen with full contrast, with a view to finding sacroiliac disease with retroperitoneal involvement; These images showed at the level of the sacroiliac joint a dense heterogeneous collection with



air content associated with cortical erosion that extends anteriorly to the psoas and iliac muscles and posteriorly to the piriformis muscle, as well as tomographic signs in relation to sacroiliac arthromyelitis with areas of abscessed collection in ipsilateral iliac psoas and piriformis muscle (figure 1).

The diagnosis of retroperitoneal abscess was raised, for which an exploratory laparotomy + abscess drainage + mixed drain was performed. Regarding the operative findings, it is mentioned that upon opening Todd's fascia, bulging of the right psoas was evident due to purulent fluid of approximately 100mL.

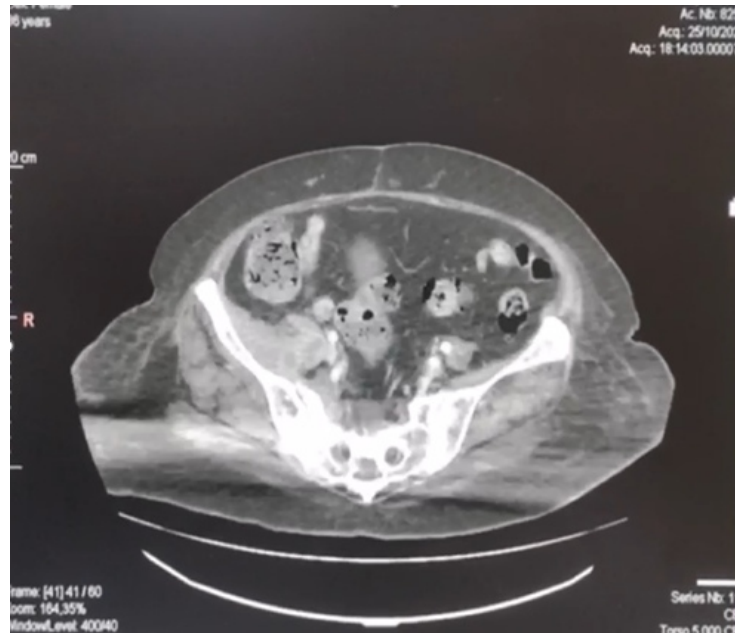


Figure 1. : In the right sacroiliac joint there is a dense heterogeneous collection with air content associated with cortical erosion that extends anteriorly to the psoas and iliac muscles and posteriorly to the piriformis muscle.

DISCUSSION

EISI is a rare disease that presents with non-specific symptoms, often causing a delay in diagnosis. The initial presentation may indicate more common conditions, such as back pain, sciatica, abscesses inside or outside the pelvis, abdominal infection, kidney stones, or pyelonephritis. ISI is usually unilateral. Typical symptoms include low-grade fever, lower back pain (occurring in up to 100% of patients), pain in the waist and back of the thigh, and difficulty walking on the affected side. Surprisingly, more than half of the reported cases were diagnosed 10 days or more after the onset of symptoms^(2,9).

Early physical examination revealed specific findings, including tenderness in the posterior region of the sacroiliac arthromyelitis and pain caused by compression of the posterior pelvis, but direct palpation of the SIA was difficult, due to its anatomical

location, requiring a provocative examination to replicate pain and symptoms: Gaenslen (forced flexion of the contralateral hip and forced hyperextension of the ipsilateral hip with the patient supine) and a positive FABERE test in up to 91.7% of patients^(10,11). These tests have been shown to be reliable with sensitivity, specificity, and positive predictive value (60%) in determining the origin of pain, but are not commonly performed in the current clinical setting due to a low index of suspicion.

Berthelot and Laslett⁽¹²⁾ reported that, on clinical examination of SIA, no clinical sign could clearly indicate pain, but that the probability of joint or periarticular pain increases when three of the five most reliable provocation tests are positive:

- 1) Iliac wings distraction maneuver
- 2) Compression maneuver of the iliac wings





- 3) Direct compression on the sacrum
- 4) Gaenslen test
- 5) Mennell test (Gaenslen test with the patient in the lateral decubitus position)

These tests must be performed on a hard surface, with sufficient duration and force to mobilize the joint and reproduce the pain. The risk of complications, recurrence and sequelae, such as chronic pain, increases with delay in diagnosis⁽¹³⁾. Approximately 50% of patients may also have leukocytosis⁽¹⁴⁾, but the most reliable laboratory tests are markers of inflammation, including ESR and CRP, and although these markers are sensitive, they are not specific for diagnosis or treatment⁽³⁾.

In the pathophysiology of ISI, infection can be caused by hematogenous dissemination of bacteria from distant sources of ISI; the subchondral circulation on the iliac side of the joint, where the arteries terminate, can serve as an entry point for microorganisms and spread posterior to the joint. Other routes are through adjacent infection, either muscular or intestinal, or by direct inoculation, as in infiltration^(7,11). CT can be used for early diagnosis because it shows inflammatory changes and an appearance consistent with ISI. Magnetic resonance imaging is the imaging modality with the highest sensitivity and specificity (95% and 100%, respectively) and is considered the reference test for confirmation of ISI⁽¹¹⁾. MRI combines good visualization of the complex anatomy of Sacroiliac arthromyelitis with the ability to identify varying degrees of inflammation and joint damage, such as the presence of joint and periarticular effusions, bone marrow edema, muscle abscesses, bone erosions and sequestration and Joint capsulitis or widening of the joint space.

Bone marrow edema in sacroiliitis spondyloarthritis occurs mainly in the hip, while in ISI, it occurs mainly in the sacrum or is distributed evenly⁽¹²⁾. On contrast-enhanced MRI, a unilateral increase in uptake is seen three days after symptom onset^(6,11-13). The definitive microbiological diagnosis can be based on blood cultures, fluid sampling by percutaneous puncture guided by radiography or CT, or surgical cleansing.

Aspiration of the sacroiliac arthromyelitis is technically difficult due to its location.

Under radioscopic guidance, a needle of sufficient caliber is placed to take a tissue sample and aspirate it from the SIJ, to send it for histopathological study, routine cultures, and tuberculosis⁽¹⁴⁾. *S. Aureus* is the most frequently isolated microorganism, between 45% and 83.3% of cases, according to different authors, followed by coagulase-negative *Staphylococcus*, group B *Streptococcus*, *Streptococcus pneumoniae*, *Enterobacteriaceae*, such as *Escherichia coli*, and *Salmonella* species, *mycobacterium catarrhalis*, *mycobacterium tuberculosis*, *haemophilus influenzae*, *brucella* species, and *pseudomona aeruginosa*^(2,17,27,28). However, in 27% to 40% of cases, cultures are negative⁽¹⁴⁾.

Delay in diagnosis and/or inadequate treatment of IBS can lead to severe consequences, such as bacteremia, septic shock, osteomyelitis or abscess formation^(13,14). Currently, there is no consensus on the duration of antibiotic treatment; The usual time is 4 to 6 weeks, although some authors^(15,16) propose 4 to 8 weeks, and others such as Matt et al.⁽¹⁷⁾ reported that the absence of clinical relapses observed in their group of 18 patients, after a minimum follow-up of 6 months, suggests that 6 to 12 weeks of antibiotic treatment are sufficient to obtain a cure. The choice of antibiotic is based on the culture and the antibiogram.

Surgical intervention is reserved for failure of conservative treatment and the presence of complications such as abscesses and osteomyelitis^(18,19). Patient follow-up is prolonged; the absence of symptoms is the first element to consider, in addition to the normalization of inflammatory parameters. Regarding imaging follow-up, it is essential to keep in mind that bone edema persists up to twenty months after completing the treatment⁽²⁰⁾.

CONCLUSION

ISI is a rare disease, but its complications can have serious and functional consequences. A high index of suspicion allows for early diagnosis and rapid initiation

of treatment. Although some diagnoses require the isolation of microorganisms in blood cultures or joint aspirates, the clinical picture of an acute episode, unilateral involvement and intense pain in the buttocks, accompanied by fever, is considered to support the diagnosis of ISI. Imaging studies, especially MRI, should be performed as soon as possible to aid in early

diagnosis. There is no consensus on the duration of antibiotic therapy, but a course of 4 to 6 weeks is most appropriate. Current information is based on reports and case series, so studies with significant samples are needed to determine the diagnosis, the minimum duration of treatment and the follow-up necessary to control this condition.

Authorship contributions: All authors participated in the conceptualization, research, methodology, resources, and writing of the original draft.

Conflicts of interest: No conflicts of interest were reported in the preparation of this work.

Financing: Self-financed.

Received: July 17, 2023.

Approved: October 27, 2023.

Correspondence: Roger Antonio Sernaque Mechato.

Address: Av. Bolívar S/N Cdra. 8. Pueblo Libre. Perú.

Telephone number: 998 995 740

Email: internistagg@gmail.com

REFERENCES

1. Diacinti D, Gioia C, Vullo F, Cannavale G, Catalano C, Valesini G. Magnetic resonance imaging findings of infectious sacroiliitis associated with iliopsoas abscess: a case report in a young male. *Reumatismo* 2018;70(04):264–267
2. Kucera T, Brtkova J, Sponer P, et al. Pyogenic sacroiliitis: diagnosis, management and clinical outcome. *Skeletal Radiol* 2015;44(01):63–71
3. Doita M, Yoshiya S, Nabeshima Y, et al. Acute pyogenic sacroiliitis without predisposing conditions. *Spine* 2003;28(18):E384–E389
4. Vinceneux P, Rist S, Bosquet A. Arthrites septiques des sacroiliaques et de la symphyse pubienne. *Rev Rhum* 2006;73:177–182
5. Muche B, Bollow M, François RJ, Sieper J, Hamm B, Braun J. Anatomic structures involved in early- and late-stage sacroiliitis in spondylarthritis: a detailed analysis by contrast-enhanced magnetic resonance imaging. *Arthritis Rheum* 2003;48(05):1374–1384
6. Canella C, Schau B, Ribeiro E, Scaffi B, Marchiori E. MRI in seronegative spondyloarthritis: imaging features and differential diagnosis in the spine and sacroiliac joints. *AJR Am J Roentgenol* 2013;200(01):149–157
7. Pertuiset É. Les autres causes de sacroiliites que les spondylarthropathies. *Rev Rhum* 2009;76:761–766
8. Osman AA, Govender S. Septic sacroiliitis. *Clin Orthop Relat Res* 1995;(313):214–219
9. Ghosh S, Narang H, Goel P, Kumar P, Soneja M, Biswas A. Atypical presentation of pyogenic iliopsoas abscess in two cases. *Drug Discov Ther* 2018;12(01):410
10. Barnes M, Bush C, Jones J. Pyogenic sacroiliitis: A rare complication of inflammatory bowel disease. *Am J Emerg Med* 2019;37(07):1395.e1–1395.e2. Doi: 10.1016/j.ajem.2019.04.017
1. Wilson JJ, Furukawa M. Evaluation of the patient with hip pain. *Am Fam Physician* 2014;89(01):27–34
2. Berthelot J, Laslett M. Par quels signes cliniques s'assurer au mieux qu'une douleur est bien d'origine sacroiliaque. *Rev Rhum* 2009;76:741–749
3. Slobodin G, Rimar D, Boulman N, et al. Acute sacroiliitis. *Clin Rheumatol* 2016;35(04):851–856
4. Vyskocil JJ, McLlroy MA, Brennan TA, Wilson FM. Pyogenic infection of the sacroiliac joint. Case reports and review of the literature. *Medicine (Baltimore)* 1991;70(03):188–197
5. Hermet M, Minichiello E, Flipo RM, et al. Infectious sacroiliitis: a retrospective, multicentre study of 39 adults. *BMC Infect Dis* 2012;12:305
6. Bernard L, Dinh A, Ghout I, et al. Duration of Treatment for Spondylodiscitis (DTS) study group. Antibiotic treatment for 6 weeks versus 12 weeks in patients with pyogenic vertebral osteomyelitis: an open-label, non-inferiority, randomised, controlled trial. *Lancet* 2015;385(9971):875–882
7. Scott KR, Rising KL, Conlon LW. Infectious sacroiliitis. *J Emerg Med* 2014;47(03):e83–e84
8. Cinar M, Sanal HT, Yilmaz S, et al. Radiological followup of the evolution of inflammatory process in sacroiliac joint with magnetic resonance imaging: a case with pyogenic sacroiliitis. *Case Rep Rheumatol* 2012;2012:509136
9. Sturzenbecher A, Braun J, Paris S, Biedermann T, Hamm B, Bollow M. RM de la artritris séptica. *Skeletal Radiol* 2000;29:212–215
10. Shemer A, Eshed I, Levinkopf M. Septic Sacroiliitis: A Diagnostic Challenge for the Clinician. *Isr Med Assoc J* 2018;20(01):58–59