



# CONGENITAL MICROTIA AND CONGENITAL AURAL ATRESIA: A LITERATURE REVIEW

MICROTIA Y ATRESIA AURAL CONGÉNITA: UNA REVISIÓN DE LA LITERATURA

Diego Marin M <sup>1,2,a</sup>

## ABSTRACT

**Introduction:** Permanent hearing loss is common at birth, and the negative consequences for language, cognitive, and social-emotional skills are particularly important. Microtia and congenital aural atresia is a disorder of the external ear that can occur in isolation or in association with another malformation. **Objective:** The objective of the present study was to know and compile the current evidence on microtia and aural atresia. The PubMed, Scopus, and SciELO databases were consulted, from the year 2010 to the year 2023. **Methods:** All the bibliographic references were searched in relation to the keywords: microtia, and aural atresia. Were evaluated review and research articles, which in general, were less than 05 years published. It was limited to articles in Spanish and English and were identified by titles. Were identified once the articles of interest, the following were considered as inclusion criteria: 1. That they examine the diagnosis and treatment of microtia and congenital aural atresia 2. They address the subject according to a systematic methodology (quantitative, qualitative, and others). **Results:** The causes of these disorders are not fully understood. In conclusion, auditory evoked potentials and audiometry are the test of choice for cases of microtia and congenital aural atresia. **Conclusion:** Surgical correction is often not the preferred treatment; the hearing result is no better than that of bone conduction devices. Likewise, the functional aspect should be prioritized over the aesthetic one since early hearing loss intervenes in the development of language in the child.

**Keywords:** Congenital microtia; Ear external; Ear canal; Hearing loss; Neonatal screening. (Source: MESH-NLM)

## RESUMEN

**Introducción:** La hipoacusia permanente es frecuente al nacer y tiene consecuencias negativas para el lenguaje, habla, habilidades cognitivas y socioemocionales. La microtia y atresia aural congénita es un trastorno del oído externo que puede ocurrir de forma aislada o asociada con otra malformación. **Objetivo:** El objetivo del presente estudio fue conocer y recopilar la evidencia actual en microtia y atresia aural. Se consultaron las bases de datos PubMed, Scopus y SciELO, a partir del año 2010 hasta 2023. **Métodos:** Se buscaron todas las referencias bibliográficas en relación con las palabras clave: microtia, atresia aural. Se evaluaron artículos de revisión e investigación, que en general, tenían menos de 05 años de publicados. Se limitó a artículos en español e inglés y se identificaron por los títulos. Una vez identificados los artículos de interés, se consideraron como criterios de inclusión: 1. Que examinaran el diagnóstico y tratamiento de la microtia y atresia aural congénita 2. Que abordaran la temática de acuerdo con una metodología sistematizada (cuantitativa, cualitativa, otras). **Resultados:** En conclusión las causas de dichos trastornos no se encuentran completamente comprendidas. Los potenciales evocados auditivos y la audiometría constituyen los exámenes de elección para los casos de microtia y atresia aural congénita. **Conclusión:** La corrección quirúrgica a menudo no es el tratamiento preferido; el resultado de la audición no es mejor que el de los dispositivos de conducción ósea. Asimismo, se debe priorizar el aspecto funcional que el estético, ya que la pérdida de la audición temprana interviene en el desarrollo del lenguaje en el niño.

**Palabras clave:** Microtia congénita; Oído externo; Conducto auditivo externo; Pérdida auditiva conductiva; Tamizaje neonatal. (Fuente: DeCS- BIREME)

<sup>1</sup> Faculty of Human Medicine. Universidad Ricardo Palma, Lima, Peru.

<sup>2</sup> Department of Neonatology. Instituto Nacional Materno Perinatal. Ministry of Health, Lima, Peru.

<sup>a</sup> Otolaryngologist.

Cite as: Marin D. Congenital microtia and congenital aural atresia: a literature review. Rev Fac Med Hum. 2024;24(4):179-188.

[doi 10.25176/RFMH.v24i4.6454](https://doi.org/10.25176/RFMH.v24i4.6454)

Journal home page: <http://revistas.urp.edu.pe/index.php/RFMH>

Article published by the Journal of the Faculty of Human Medicine of the Ricardo Palma University. It is an open access article, distributed under the terms of the Creative Commons License: Creative Commons Attribution 4.0 International, CC BY 4.0 (<https://creativecommons.org/licenses/by/4.0/>), which allows non-commercial use, distribution and reproduction in any medium, provided that the original work is duly cited. For commercial use, please contact [revista.medicina@urp.edu.pe](mailto:revista.medicina@urp.edu.pe)

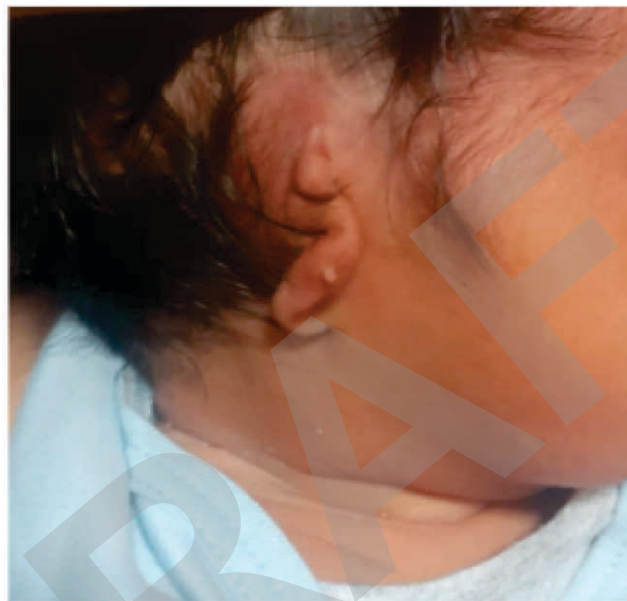



## INTRODUCTION

Congenital hearing loss has a prevalence of 1 to 2 per 1,000 newborns and has negative consequences for language, speech, cognitive, and socio-emotional skills<sup>(1)</sup>. The hearing loss experienced by patients with microtia and aural atresia is usually conductive or mixed in most cases<sup>(2)</sup>. According to the World Health Organization, more than 5% of the global population suffers from disabling hearing loss and requires rehabilitation (34 million children)<sup>(3)</sup>.

Microtia is a congenital defect of the auricle at birth, ranging from incomplete development to complete absence, and can occur in isolation or associated with other malformations<sup>(2,4,5)</sup>. A patient with microtia, without an associated syndrome, can generally live a normal and productive life<sup>(2)</sup>. The most common presentation of microtia is grade III, which consists of hypoplasia of the entire cartilaginous framework with a lobular remnant (see figure 1)<sup>(6)</sup>.



**Figure 1.** Patient with grade III Meurman microtia in the right ear.  
Source: Instituto Nacional Materno Perinatal.

Aural atresia is a disorder characterized by varying degrees of congenital hypoplasia of the external auditory canal and is often present with microtia<sup>(6,7)</sup>.

It is classified according to the following types:

**Type A (stenosis):** The fibrocartilaginous and bony portions of the external auditory canal are present but narrow.

**Type B (partial atresia):** Only some parts of the fibrocartilaginous or bony portions of the external auditory canal are present, with a rudimentary tympanic membrane.

**Type C (total atresia):** Both the fibrocartilaginous and bony portions of the external auditory canal, as well as the tympanic membrane, are absent<sup>(6)</sup>.

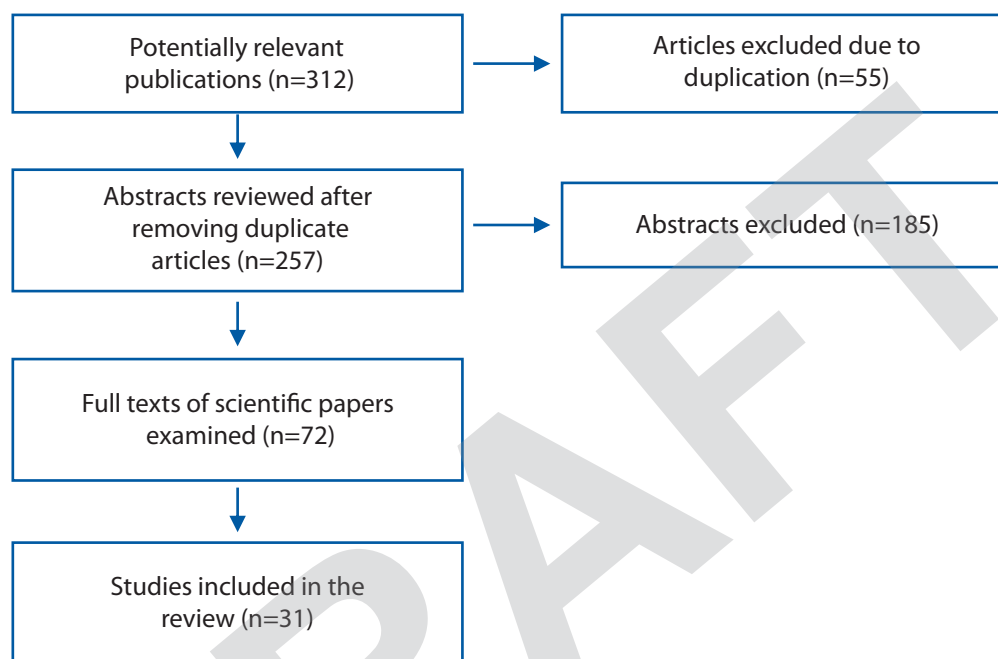
The objective of this study was to review and compile the current evidence on congenital microtia and aural atresia.

### Methodology for search and selection of results

The review was conducted through an electronic bibliographic search based on evidence, with articles in English and Spanish from PubMed/Medline, Scopus, Clinical Key, and SciELO, covering the period from 2010

to 2023 (see figure 2). All references in both Spanish and English with the keywords "congenital microtia" and "congenital aural atresia" were searched. Review and research articles were evaluated, generally published within the last five years. Once relevant articles were identified, the inclusion criteria were as follows: 1. Articles examining the diagnosis and treatment of congenital microtia and aural atresia, and 2. Articles

addressing the topic with a systematic methodology (quantitative, qualitative, or other approaches). After a full-text evaluation, 31 studies were selected for inclusion in this article. The review process spanned four months (from February 2023 to June 2023). This work is part of the Research Lines of the Universidad Ricardo Palma 2021-2025<sup>(31)</sup>.



**Figure 2.** Flowchart of article search and information selection.

## DEVELOPMENT OF THE TOPIC

### Epidemiology

Microtia has an incidence of 1 to 10 per 10,000 births<sup>(15)</sup>, with significant social implications as affected individuals may experience psychological problems due to this visible and difficult-to-conceal defect<sup>(13)</sup>. Microtia is associated with aural atresia in 75% of cases<sup>(9)</sup>. In Mexico, a prevalence of 7.37 per 10,000 live births has been reported<sup>(14)</sup>. In Peru, there is no national data to determine the prevalence of microtia and aural atresia<sup>(15)</sup>.

Microtia can be unilateral or bilateral<sup>(29)</sup>. 90% of microtia cases are unilateral, with the right ear being more affected than the left ear<sup>(5,6,11,12,16)</sup>, and it is more common in males than females<sup>(5-7,12)</sup>.

This malformation is associated with a syndrome in 30-60% of patients<sup>(6,17)</sup>. In unilateral cases, microtia is defined as a size discrepancy between the ears that exceeds the normal variation<sup>(18)</sup>. Bilateral microtia is defined as an external ear length more than two standard deviations below the mean. In severe cases, the auricle is completely absent (anotia).

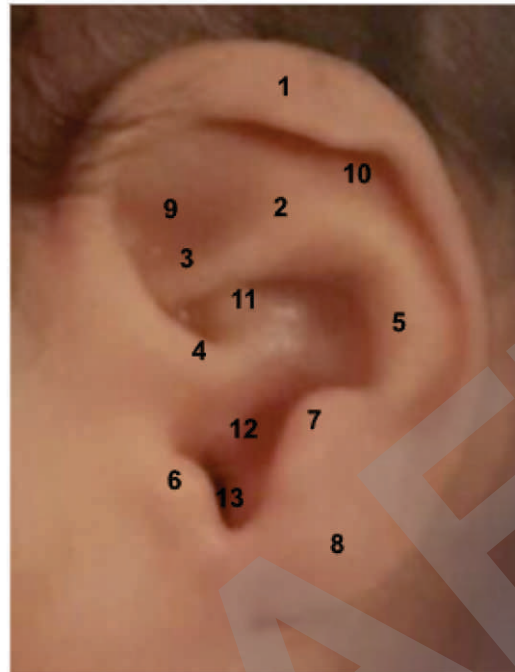
### Embryology and anatomy

The somatic ectoderm plays a role in the formation of the external and internal ear, forming the epithelial elements of the auricle, external auditory canal, the outer layer of the tympanic membrane, and the membranous labyrinth of the inner ear<sup>(19)</sup>. The auricle develops from three auricular prominences of the first branchial arch<sup>(13,20)</sup>.



It forms from the fusion of six mesenchymal buds or His auricular prominences on the surface of the embryo during the fifth week of intrauterine development,

with its development completing by the twelfth week <sup>(21)</sup>. The anatomy of the auricle is shown in Figure 3.



**Figure 3.** Anatomy of the auricle. 1. Helix, 2. Superior crus, 3. Inferior crus, 4. Helix root, 5. Antihelix, 6. Tragus, 7. Antitragus, 8. Earlobe, 9. Triangular fossa, 10. Scaphoid fossa, 11. Concha cymba, 12. Concha cavum, 13. Intertragal notch. Source: Instituto Nacional Materno Perinatal (INMP). (INMP).

The external auditory canal forms from the 8th week, and its epithelium develops from the first branchial groove <sup>(22)</sup>. It measures 2.5 cm, extending from the concha to the tympanic membrane and consists of two zones:

1. Outer cartilaginous third
2. Inner two-thirds bony portion<sup>(22)</sup>

It has an S-shape, initially directed inward, forward, and slightly upward; then it curves backward and upward, and finally inward, forward, and slightly downward <sup>(22)</sup>. Early disruptions in this process lead to anotia or microtia, while later disruptions result in minor auricular malformations. Congenital anomalies of the external and middle ear affect structures derived mainly from the first and second branchial arches, the

first groove, and the first pharyngeal pouch.

### Etiopathogenesis

The causes are not fully understood and remain unclear <sup>(17,23)</sup>. Genetic and environmental factors can result in malformation during the embryogenesis of the external, middle, or inner ear, primarily between the third and tenth weeks of gestation <sup>(19)</sup>. Embryologically, there is a failure in the development and/or migration of mesodermal and cartilaginous components<sup>(23)</sup>.

External auditory canal atresia may be due to the failure of reabsorption of the meatal plug or overdevelopment of the Reichert's cartilage (second branchial arch) <sup>(19)</sup>. Malformations of the malleus and incus may result from defective differentiation of Meckel's cartilage (first branchial arch), leading to malformed ossicles or abnormal fixation of the malleus and incus<sup>(23)</sup>.

### Associated factors

Ethnicity, male gender, low birth weight, acute maternal viral illness, maternal education level, maternal diabetes, multiple births, and maternal use of thalidomide, retinoids, aminoglycosides, alcohol, and smoking during pregnancy are associated factors for microtia<sup>(9,23,24,29)</sup>. Additionally, infections like rubella, cytomegalovirus, or toxoplasma gondii, and metabolic disorders such as hypothyroidism or endemic cretinism are associated with microtia<sup>(23,24)</sup>.

Higher folate intake during pregnancy has been found to reduce the incidence of microtia<sup>(24)</sup>. Less than 50%

of patients with microtia are associated with syndromes such as craniofacial microsomia, Treacher Collins syndrome, Goldenhar syndrome, Crouzon syndrome, Moebius syndrome, Fanconi syndrome, DiGeorge syndrome, Pierre Robin syndrome, CHARGE syndrome, VACTERL syndrome, labyrinthine aplasia, and branchiootorenal syndrome<sup>(7,9,23,24)</sup>. Additionally, a study has associated microtia with altitude (>2000 meters above sea level) in certain cities<sup>(28)</sup>.

### Classifications

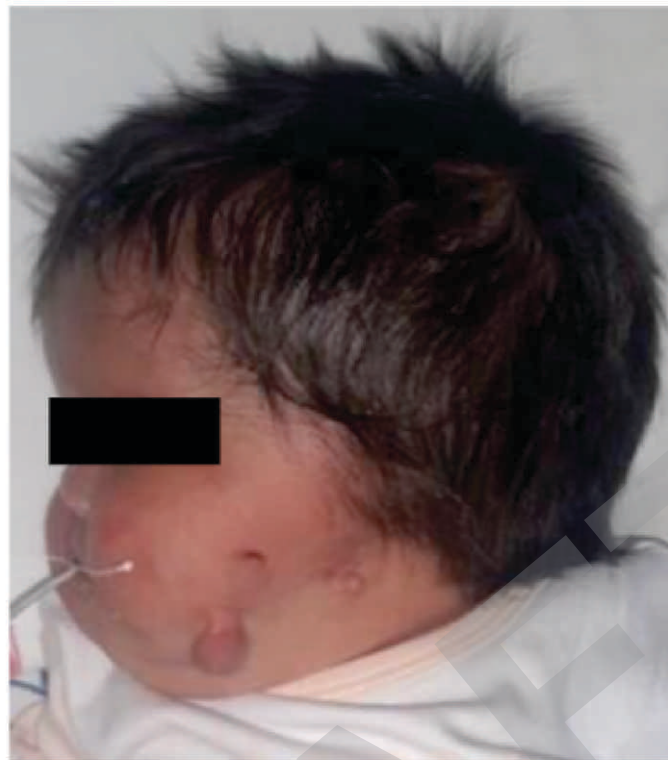Tanzer (27) and Meurman (25) classified microtia (see Tables 1 and 2).

**Table 1.** Tanzer Classification.

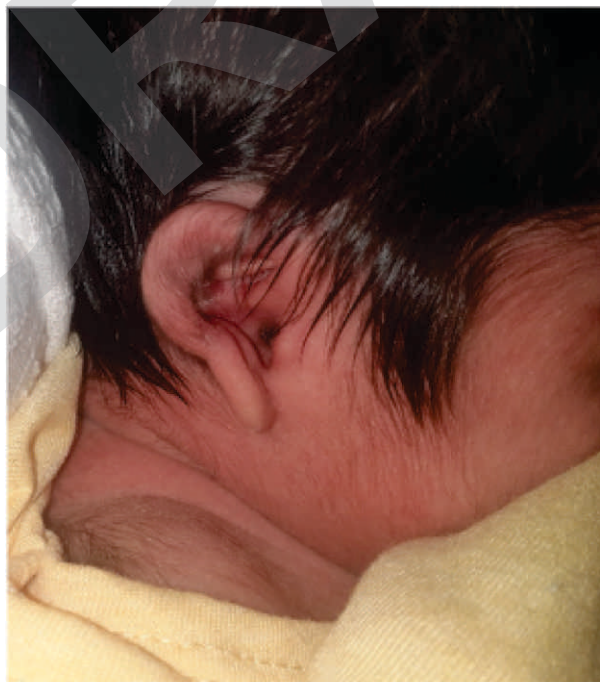<b>I Anotia (see figure 3)</b>
<b>II Complete hypoplasia (microtia):</b>
A. With external auditory canal atresia
B. Without external auditory canal atresia
<b>III Hypoplasia of the middle 1/3 of the auricle</b>
<b>IV Hypoplasia of the upper 1/3:</b>
A. Horn-shaped or cup-shaped ear (see Figure 4)
B. Cryptotia

**Table 2.** Meurman Classification.

<b>I</b> Small auricle, but harmonious
<b>II</b> Vestigial remnants of the auricle, external auditory canal atresia
<b>III</b> Almost complete absence of the auricle, remnant in the form of a lobe



**Figure 4.** Patient with anotia in the left ear plus melotia  
Source: Instituto Nacional Materno Perinatal.



**Figure 5.** Patient with hypoplasia of the upper third of the right ear auricle  
Source: Instituto Nacional Materno Perinatal.



## Diagnosis

The diagnosis of microtia and aural atresia is clinical, supported by complementary exams. During the clinical exam, the shape of the auricle (smaller than normal ears), its implantation, and stigmata (fistulas, appendages, or nodules) should be observed<sup>(23,29)</sup>. The meatus, external auditory canal (abnormally narrow, blocked, or absent), and the tympanic membrane should also be examined<sup>(23,29)</sup>. Additionally, it is important to assess the temporomandibular joint (soft tissue dysplasia) and the ascending branch of the mandible, as well as the appearance and conformation of the cranial sutures. Facial asymmetries, maxillary hypoplasias (upper or lower), oral opening, cleft palate, or submucosal cleft, and characteristics of the neck, chest, and upper and lower limbs should also be evaluated, along with the presence of branchial cysts<sup>(23)</sup>.

## Complementary examinations

Otoacoustic emissions are recommended to evaluate the healthy ear. A microphone in the external auditory canal detects these low-intensity otoacoustic emissions<sup>(1)</sup>.

The pediatrician or family physician usually has the first contact with the child and must be aware of the risk factors for hearing loss and the need for hearing screening. The otolaryngologist must have the necessary equipment and training in pediatric diagnosis. Auditory evoked potentials are the complementary exams of choice. Brainstem auditory evoked potentials (BAEP) or BERA<sup>(1)</sup> measure the electrical response of the auditory pathway at the brainstem level, including the cochlea and retrocochlear pathway, using surface electrodes.

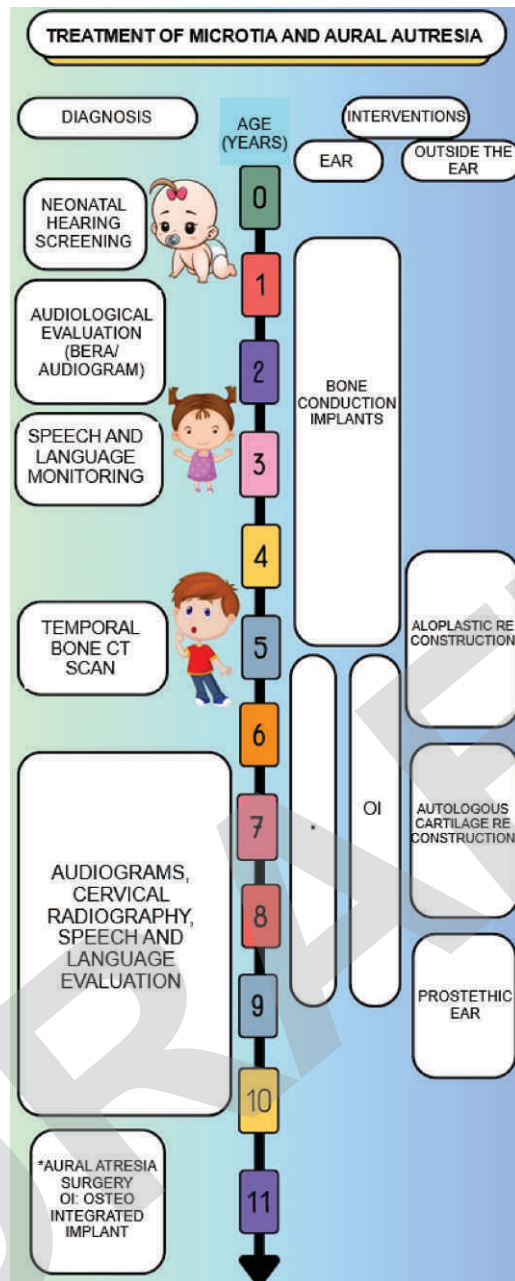
Additionally, auditory steady-state response (ASSR) measures the hearing level and can evaluate the bone conduction pathway. Free-field audiometry, play audiometry, and tonal audiometry are indicated depending on the child's age<sup>(21,25)</sup>.

Tympanometry is recommended for permeable canals or the ear contralateral to dysgenesis to determine possible malformations of the ossicular chain in apparently normal ears<sup>(23)</sup>. Regarding imaging studies, a computed tomography (CT) scan of the temporal bones with thin axial and coronal slices without contrast is requested. This allows for the evaluation of the temporal bone, tympanic bone, mastoid, middle ear cavity, its relationship to the facial nerve, ossicular chain, and the conformation of the bony labyrinth. A CT scan of the temporal bones is performed around the ages of five to six years, or earlier in cases of bilateral dysgenesis or suspected cholesteatoma<sup>(25)</sup>. Magnetic resonance imaging (MRI), specifically of the posterior fossa, is requested to evaluate the membranous structures of the cochlea, posterior labyrinth, and cranial nerves.

## Treatment

A bone vibrator device, similar to a headband or soft band, is recommended before patients become candidates for osteo-integrated bone vibrator surgery to stimulate the auditory nerve<sup>(34)</sup>. The use of bone conduction devices in young patients aids in the acquisition of language skills during critical periods of life<sup>(34)</sup>.

Reconstructive options for microtia are as follows: (see Figure 5)



**Figure 6.** Treatment of microtia and aural atresia (9, 24).

Source: Bly RA, Bhrany AD, Murakami CS, Sie KC. Microtia Reconstruction. *Facial Plast Surg Clin North Am.* 2016;24(4):577-591. doi: 10.1016/j.fsc.2016.06.011.

<https://www.ncbi.nlm.nih.gov/pmc/articles/PMC5950715/>

1. A portion of autologous costal cartilage placed subcutaneously.
2. Implanted artificial material, including a porous polyethylene implant placed subcutaneously or under a vascularized fascial flap and skin graft.
3. An ear prosthesis adhered to the skin with medical adhesive or through osseointegrated implants.

The management of aural atresia includes bone conduction implants, middle ear implants, and surgical reconstruction<sup>(5,8)</sup>. Among these options, canaloplasty has the advantage of reconstructing the external auditory canal and reducing the need for hearing devices<sup>(8)</sup>. As for bone conduction implants, there are BAH (Bone Anchored Hearing Aid), Bonebridge, and Sophono.



The indications for BAHA are as follows:

Patients over five years of age with unilateral or bilateral auditory dysgenesis who present conductive or mixed hearing loss with bone conduction above 45 dB, who cannot use an air-conduction hearing aid, may be candidates for it.

Prosthetics should be considered from 3-4 months of age if the hearing loss is bilateral. When the external auditory canal is permeable on at least one side, an air-conduction prosthesis is recommended<sup>(19)</sup>.

The Bonebridge uses a bone conduction system that stimulates the cochlea directly through skull vibration<sup>(19)</sup>. The internal components include a receiver coil attached to the floating mass transducer for bone conduction<sup>(20)</sup>.

The indications are the same as for the BAHA<sup>®</sup> device<sup>(19)</sup> and these are as follows:

- In the case of unilateral microtia, most authors agree not to recommend surgical hearing rehabilitation due to surgical risks (labyrinthitis, facial paralysis, canal stenosis) and inconsistent results (insufficient hearing in at least 66% of cases).

Functional surgery is indicated when microtia is bilateral starting from the age of five. Otherwise, an osseointegrated prosthesis may be proposed<sup>(25)</sup>. In aural atresia, surgical correction is often not the

preferred treatment; the hearing outcome is not better than that of bone conduction devices, and surgery may be associated with recurrence or complications such as meatal stenosis<sup>(31)</sup>.

With the Sophono implant, the processor can be attached as soon as the surgical wound has fully healed, usually within three or four weeks. The implant remains completely hidden under the skin, causing less aesthetic disruption and reducing the risk of implant damage from manipulation<sup>(33)</sup>.

Patients should be diagnosed and treated by a multidisciplinary team: family physician, pediatrician, geneticist, pediatric audiologist, pediatric otolaryngologist, or pediatric plastic surgeon. The options for both auditory and auricular reconstruction should be considered and coordinated during the neonatal period<sup>(26,30)</sup>.

## CONCLUSION

Systematic studies are needed in Latin America to determine the prevalence of congenital microtia and aural atresia. Auditory evoked potentials and audiometry are the tests of choice for cases of congenital microtia and aural atresia. Surgical correction is often not the preferred treatment, because hearing outcomes are not better than those of bone conduction devices. Additionally, the functional aspect should be prioritized over the aesthetic, as early hearing loss affects the child's language development.

---

**Authorship contribution:** DMM participated in the conceptualization, research, methodology, resources, and drafting of the original manuscript.

**Funding:** Self-funded.

**Conflict of interest:** The author declares no conflicts of interest.

**Received:** April 02, 2024.

**Approved:** August 20, 2024.



**Correspondence:** Diego Marin Marin.

**Address:** Jr. Rio Amazonas 3215 Urb. Canto Rey. San Juan de Lurigancho, Lima, Perú.

**Telephone:** (+51) 950181879

**Email:** [diego.franco.marin@gmail.com](mailto:diego.franco.marin@gmail.com)

## REFERENCES

- Marin Marin D. Tamizaje auditivo neonatal: Guía para el diagnóstico temprano. *Rev Peru Investig Matern Perinat.* 2022; 11(4):35-42. doi: <https://doi.org/10.33421/inmp.2022311>
- Andrews J, Kpacz A, Hohman M. StatPearls: Ear Microtia. [Internet]. Treasure Island (FL): StatPearls Publishing; 2023 [citado el 05 de junio de 2023]. Disponible en: <https://www.ncbi.nlm.nih.gov/books/NBK563243/>
- Organización Mundial de la Salud. Sordera y pérdida de la audición: Datos y cifras [Internet]. 2024. [citado el 06 de agosto de 2024]. Disponible en: <https://www.who.int/es/news-room/fact-sheets/detail/deafness-and-hearing-loss>
- Al-Sulaimani AK, Al-Khabori MS, Haridi KM, Al-Busaidi SS. Prevalence and characteristics of microtia in Oman: 37 Years analysis. *J Plast Reconstr Aesthet Surg.* 2023;76:292-94. doi: 10.1016/j.bjps.2022.10.0471.
- Cywka KB, Król B, Skarzyński PH. Effectiveness of Bone Conduction Hearing Aids in Young Children with Congenital Aural Atresia and Microtia. *Med Sci Monit.* 2021;27:1-8. doi: 10.12659/MSM.933915.
- Truong MT, Liu YC, Kohn J, Chinnadurai S, Zopf DA, Tribble M, et al. Integrated microtia and aural atresia management. *Front Surg.* 2022;9:1-18. doi: 10.3389/fsurg.2022.944223.
- Abdel-Aziz M. Congenital aural atresia. *J Craniofac Surg.* 2013;24(4):418-22. doi: 10.1097/SCS.0b013e3182942d11.
- Kim MB, Cho YS. Acoustic Reflex After Surgical Repair in Patients with Congenital Aural Atresia. *J Int Adv Otol.* 2022;18(6):482-87. doi: 10.5152/iao.2022.21514.
- Abrol A, Bly R, Sie KCY, Bhrany AD. Contemporary Management of Microtia. *Facial Plast Surg.* 2022;38(4):393-404. doi: 10.1055/a-1854-2352.
- Volgger V, Schiefler IT, Müller J, Schrötlmair F, Pollotzek M, Hempel JM. Audiological results and subjective benefit of an active transcutaneous bone-conduction device in patients with congenital aural atresia. *Eur Arch Otorhinolaryngol.* 2022;279(5):2345-52. doi: 10.1007/s00405-021-06938-8.
- Yang L, Chen P, Liu Y, Yang J, Zhao S. Clinical manifestations and treatment strategies for congenital aural atresia with temporomandibular joint retroposition: a retrospective study of 30 patients. *J Otolaryngol Head Neck Surg.* 2023;52(1):24. doi: 10.1186/s40463-022-00615-4.
- Gautam R, Kumar J, Pradhan GS, Meher R, Arya S. Congenital Aural Atresia: What the Radiologist Needs to Know? *Curr Probl Diagn Radiol.* 2022;51(4):599-616. doi: 10.1067/j.cpradiol.2021.06.017.
- Nazer J, Lay G, Cifuentes L. Prevalencia de nacimiento de microtia-anotia. *Maternidad del Hospital Clínico de la Universidad de Chile, período 1983-2005.* *Rev Méd Chile.* 2006 [citado el 05 de junio 2023]; 134:1295-1301. Disponible en: [https://www.scielo.cl/scielo.php?script=sci\\_arttext&pid=S0034-98872006001000012](https://www.scielo.cl/scielo.php?script=sci_arttext&pid=S0034-98872006001000012)
- Aguinaga M, Frías S, Arenas D, Morán V. Microtia-atresia: aspectos clínicos, genéticos y genómicos. *Bol Med Hosp Infant Mex.* 2014 [citado el 05 de junio 2023]; 71 (6): 387-95. Disponible en: [https://www.scielo.org.mx/scielo.php?script=sci\\_arttext&pid=S1665-11462014000600010](https://www.scielo.org.mx/scielo.php?script=sci_arttext&pid=S1665-11462014000600010)
- Bardales M. Impacto del uso de sistemas de conducción ósea en niños con microtia [Tesis de maestría]. Trujillo, Perú: Universidad Privada Antenor Orrego; 2021 [citado el 05 de junio 2023]. Disponible en: <https://repositorio.upao.edu.pe/handle/20.500.12759/8843>
- Hunter A, Frías JL, Gillissen-Kaesbach G, Hughes H, Jones KL, Wilson L. Elements of morphology: standard terminology for the ear. *Am J Med Genet A.* 2009;149(1):40-60. doi: 10.1002/ajmg.a.32599.
- Shibazaki R, Satoru N. Preferential Associated Malformation in Patients With Anotia and Microtia. *The journal of craniofacial surgery.* 2019; 30 (1): 66-70. doi: <https://doi.org/10.1097/scs.00000000000004915>
- Ferrario VF, Sforza C, Ciusa V, Serrao G, Tartaglia GM. Morphometry of the normal human ear: a cross-sectional study from adolescence to mid-adulthood. *J Craniofac Genet Dev Biol.* 1999 [citado el 10 de junio 2023]; 19(4):226-33. Disponible en: <https://pubmed.ncbi.nlm.nih.gov/10731092/>
- Orfila D, Tiberti L. Atresia congénita del oído y su manejo. *Rev. Med. Clin. Condes.* 2016; 27 (6): 880-91. doi: <https://doi.org/10.1016/j.rmclc.2016.09.018>
- Clarke B. Otorrinolaringología pediátrica: Enfermedades del oído externo, [Internet]. España: Elsevier; 2020 [citado el 05 de junio de 2023]. 383p. Disponible en: <https://www.clinicalkey.es/#/browse/book/3-s2.0-C20190000271>
- Isaacson G. UptoDate: Congenital anomalies of the ear [Internet]. 2022 [citado el 05 de junio de 2023]. Disponible en: [https://www.uptodate.com/contents/congenital-anomalies-of-the-ear?search=microtia&source=search\\_result&selectedTitle=1~16&usage\\_type=default&display\\_rank=1](https://www.uptodate.com/contents/congenital-anomalies-of-the-ear?search=microtia&source=search_result&selectedTitle=1~16&usage_type=default&display_rank=1)
- Marin C, López A, Zarante I. Microtia: una malformación olvidada. Etiología genética y estado del arte. *Universitas Médica* [Internet]. 2006 [citado el 05 de junio de 2023]; 47 (1): 80-90. Disponible en: <https://www.redalyc.org/pdf/2310/231018678008.pdf>.
- Ministerio de salud. Guía de Práctica Clínica de Microtia de la Sub Unidad de Atención Integral Especializada del Paciente de Especialidades Quirúrgicas: Guía de Práctica Clínica de Microtia [Internet]. Perú: Instituto Nacional de Salud del Niño-San Borja; 2018 [citado el 05 de junio de 2023]. 24p. Disponible en: <https://www.insnsb.gob.pe/guias-de-practica-clinicas/>
- Bly RA, Bhrany AD, Murakami CS, Sie KC. Microtia Reconstruction. *Facial Plast Surg Clin North Am.* 2016;24(4):577-91. doi: 10.1016/j.fsc.2016.06.011.
- Teissier N, Benchaat T, Elmaleh M, Van Den Abbeele T. Malformaciones congénitas del oído externo y del oído medio. *EMC-Otorrinolaringología.* 2008; 37(4):1-11. doi: 10.1016/S1632-3475(08)53552-1.
- Zhang TY, Bulstrode N, Chang KW, Cho YS, Frenzel H, Jiang D, et al. International Consensus Recommendations on Microtia, Aural Atresia and Functional Ear Reconstruction. *J Int Adv Otol.* 2019;15(2):204-8. doi: 10.5152/iao.2019.7383.
- Tanzer R. Total reconstruction of the external ear. *Plast Reconstr Surg Transplant Bull.* 1959;23(1):1-15. doi: 10.1097/0006534-195901000-00001.
- Gonzales GF. Impacto de la altura en el embarazo y en el producto de la gestación. *Rev Peru Med Exp Salud Publica.* 2012;29(2):242-9. doi: 10.1590/s1726-46342012000200013.
- Chen X, Zhang R. Microtia epigenetics: An overview of review and new viewpoint. *Medicine (Baltimore).* 2019;98(41):1-7. doi: 10.1097/MD.00000000000017468.
- Lancer H, Hood K, Halliday E, Tzifa K, Lloyd M, McDermott AL. Experience of the 'Ear Glove' in children with microtia. *Int J Pediatr Otorhinolaryngol.* 2022;160:111254. doi: 10.1016/j.ijporl.2022.111254.
- Lee M, Cho Y, Han G, Oh J. Current Treatments for Congenital Aural Atresia. *J Audiol Otol.* 2020;24(4):161-66. doi: 10.7874/jao.2020.00325.
- Universidad Ricardo Palma. Líneas de Investigación [Internet]. Universidad Ricardo Palma [consultado el 01 de abril de 2024]. Disponible en: <https://www.urp.edu.pe/vicerrectorado-de-investigacion/lineas-de-investigacion/>.
- Escorihuela V, Llópez I, Pitarch I, Latorre E, Marco J. Experiencia inicial con el implante osteointegrado Alpha 1 de Sophono. *Acta Otorrinolaryngol Esp.* 2021; 65 (6): 361-64. Doi: 10.1016/j.otorri.2014.01.005.
- Sun L, Ping L, Fan X, Wang J, Chen X. Simulator Verification Is Potentially Beneficial for the Fitting of Softband Bone Conduction Hearing Devices in Young Children. *Otol Neurotol.* 2024;45(7):500-8. Doi: 10.1097/MAO.00000000000004245.

