



TOXIC MEGACOLON. CASE REPORT

MEGACOLON TÓXICO: A PROPÓSITO DE UN CASO

Roger Sernaque Mechato ^{1,2a,b}, Stephanie Tahne Castillo Arias ^{1,c}, Silvana Ñaupari Jara ^{1,d},
Flor Milagros Mendoza Barreto ^{1,e}

ABSTRACT

Introducción: Toxic megacolon is a fatal disease, most commonly occurring as a complication of inflammatory bowel disease, infections, and intestinal ischemia. It is characterized by the presence of bloody diarrhea, abdominal distension, signs of systemic toxicity, and segmental colonic dilation is observed in imaging studies. For the diagnosis, according to the Jalan criteria, colonic dilation of more than 6 cm is taken into account, three of the following: fever, tachycardia, leukocytosis or anemia, and any of the following criteria: hypotension, hypovolemia, electrolyte disorder and altered mental status. **Clinical case:** This article presents the case of a female patient who was admitted with abdominal pain and chronic diarrhea with an imaging study showing dilation of the entire colonic framework. **Conclusion:** The corresponding studies were carried out which indicated that she had a toxic megacolon due to colitis. ulcerative, receives medical treatment with favorable evolution, is discharged and readmitted for septic shock, studies are performed and Clostridium difficile infection is identified, antibiotic treatment is started but the evolution is unfavorable, which caused the death of the patient. The present case represents the high mortality of this disease.

Keywords: Toxic megacolon; Ulcerative colitis; Clostridium difficile; Shock. (Source: MESH-NLM)

RESUMEN

Introducción: El megacolon tóxico es una enfermedad mortal, que se presenta, con mayor frecuencia, como una complicación de la inflamación intestinal, infecciones e isquemia intestinal. Se caracteriza por la presencia de diarrea sanguinolenta, distensión abdominal, signos de toxicidad sistémica y, en estudios de imagen, se observa dilatación colónica segmentaria. Para el diagnóstico, según los criterios de Jalan, se tiene en cuenta la dilatación colónica más de 6 cm, tres de los siguientes: fiebre, taquicardia, leucocitosis o anemia, y cualquiera de los siguientes criterios: hipotensión, hipovolemia, trastorno electrolítico y estado mental alterado. **Caso clínico:** En este artículo, se presenta el caso de una paciente mujer que ingresa por cuadro de dolor abdominal y diarrea crónica con estudio de imagen, en la que se visualiza dilatación de todo el marco colónico. Se realizan los estudios correspondientes y se diagnostica megacolon tóxico por colitis ulcerativa, por lo que recibe tratamiento médico con evolución favorable. Es dado de alta y reingresa por shock séptico, se realizan estudios y se identifica infección por Clostridium difficile. **Conclusión:** Se inicia tratamiento antibiótico, pero presenta evolución desfavorable, lo que ocasionó el fallecimiento de la paciente. El presente caso representa la alta mortalidad de esta enfermedad.

Palabras clave: Megacolon tóxico; Colitis ulcerativa; Clostridium difficile; Shock. (Fuente: DeCS- BIREME)

¹ Hospital Santa Rosa Lima Perú.

² Universidad Continental.

^a Medical internist.

^b Head of the Department of Medicine.

^c Gastroenterologist.

^d Family and Community Physician.

^e Master in Public Health.

Cite as: Sernaque Mechato R, Castillo Arias ST, Ñaupari Jara S, Mendoza Barreto FM. Toxic megacolon. Case report. Rev Fac Med Hum. 2024;24(1):203-210. doi:10.25176/RFMH.v24i1.6468

Journal home page: <http://revistas.urp.edu.pe/index.php/RFMH>

Article published by the Journal of the Faculty of Human Medicine of the Ricardo Palma University. It is an open access article, distributed under the terms of the Creative Commons License: Creative Commons Attribution 4.0 International, CC BY 4.0 (<https://creativecommons.org/licenses/by/4.0/>), which allows non-commercial use, distribution and reproduction in any medium, provided that the original work is duly cited. For commercial use, please contact revista.medicina@urp.edu.pe





INTRODUCTION

Toxic megacolon was first described in 1930 as colonic dilation associated with sepsis, but in 1950 Marshak defined it as segmental or total colonic distention greater than 6 cm concomitant with acute colitis and systemic symptoms⁽¹⁾. The term "toxic megacolon" implies a rare but severe and life-threatening complication of inflammation of the colon; it is characterized by total or segmental colonic distension greater than 6 cm, which is not caused by obstruction or other types of colonic dilation such as Ogilvie syndrome or Hirschsprung disease, associated with signs of systemic toxicity and inflammatory, ischemic or infectious etiology of the colon⁽²⁻⁴⁾.

The most common cause of toxic Megacolon was inflammatory bowel disease (51.6%), followed by septicemia (10.2%) and intestinal infections (4.1%). Some studies report that in inflammatory bowel disease, the incidence is higher in patients with ulcerative colitis (UC) by 8-10%, compared to Crohn's disease (CD) with 2.3%. Among the infectious causes, the most common is *Clostridium difficile* infection⁵. The diagnosis of toxic megacolon according to Jalan et al includes: (a) radiographic evidence of colonic dilation of more than 6 cm, especially in the transverse colon; (b) three of the following: fever (> 38.6 °C), tachycardia (> 120 beats/min), leukocytosis (> 10.5 × 10³/μl), or anemia; and (c) any of the following: hypotension, hypovolemia, altered mental status, or electrolyte disorders⁽⁶⁾.

Common nonspecific laboratory abnormalities associated with toxic megacolon include leukocytosis with prominent neutrophilia, especially in cases of *C. difficile* colitis, anemia due to gastrointestinal blood loss, metabolic alkalosis secondary to volume depletion, hypokalemia, hypoalbuminemia, and elevated inflammatory markers, including Sedimentation rate and C Reactive Protein⁽⁷⁾. The main objective of treatment is to reduce inflammation, improve colonic motility, and prevent colonic perforation. It begins with hydration, management of hydroelectrolyte disorders, antibiotic therapy, and

treating the cause of the toxic megacolon. Indications for surgery are colonic perforation, necrosis or total ischemia, abdominal compartment syndrome, clinical signs of peritonitis, and organ failure⁽⁷⁾. The aim of this article is to present a case of rare toxic megacolon at the Hospital Santa Rosa.

CLINICAL CASE

A 64-year-old female patient from Lima with a history of hypothyroidism, osteoporosis, and depression with regular medication of levothyroxine 0.1 mg per day. She was admitted as an emergency due to a clinical condition lasting more than 2 months, characterized by liquid stools without mucus without blood (4 times a day), with diffuse abdominal pain. Four days before admission, he presented nausea, vomiting with abdominal distention, early fullness and fever.

Vital functions on admission: BP: 110/70, HR: 85 beats per minute, RR: 18, T: 37°C, ST02: 98%.

On physical examination: in poor general condition, hydration and nutrition. Abdomen: distended, soft, depressible, increased fluid sounds, diffuse tenderness, no visceromegaly palpable. An abdominal ultrasound was performed where signs of colitis associated with an inflammatory process in the left iliac fossa and free fluid in the 38cc cavity were observed. Hydropic vesicle. Moderate diffuse hepatic steatosis.

Patient with medical management presents unfavorable evolution and increased pain and abdominal distension. An abdominal tomography was performed: diffuse concentric parietal thickening of up to 5 mm from the cecum to the sigmoid/rectum, with marked adjacent fatty striation, as well as loss of the usual haustra. Likewise, the presence of parietal fat density is observed at the level of the cecum and ileocecal valve. The caliber reaches 42 mm, with some hydro-aerial levels. Omental fat streaks. Little free fluid at the perihepatic level, in the parietocolic gutters and in the pelvis (fig. 1). Suggestive of toxic megacolon. Auxiliary examinations are requested (Table 1).

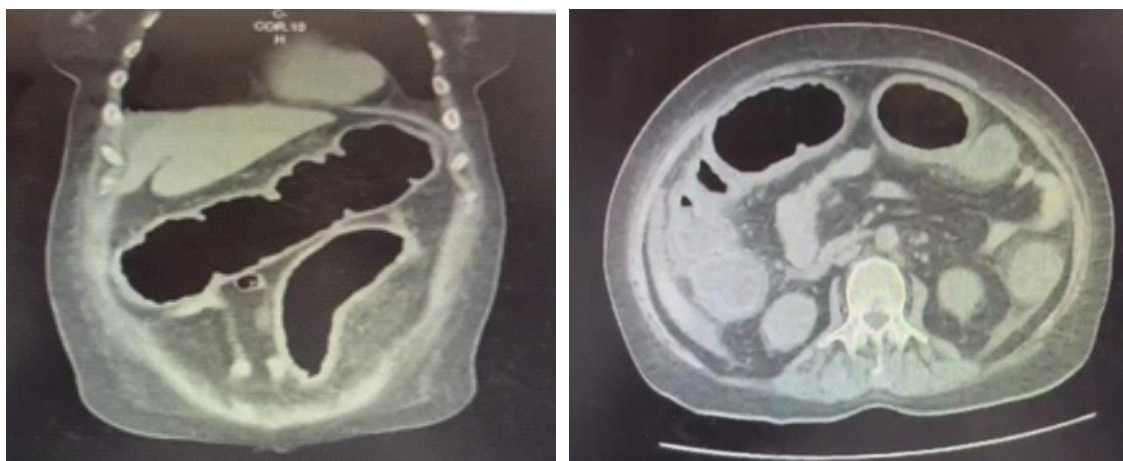


Figure 1. Abdominal tomography with contrast where it is observed through A) Coronal section of complete abdomen and B) Axial section showing colonic dilation with wall thickening.

Table 1. Auxiliary exams.

Laboratory Exams	Day 1	Day 2
Leukocytes	46160	26840
Hb	15.2	12.6
Hematocrit	43	37
Platelets	646000	599000
Basted	7 %	11 %
Segmented	85 %	81 %
Lymphocytes	6 %	4 %
Pt/ Inr	14.7/1	
Sodium	134	130
Potassium	4.4	3.96
Chorine	95	97
Urea	84	
Creatinine	2.06	2.68
Crp	49.8	
Procalcitonin	5.75	2100
Fecal Calprotectin		

According to imaging and laboratory results (Table 1), the diagnosis of toxic megacolon is confirmed. Patient receives antibiotic treatment with meropenem, intravenous hydration and due to high suspicion of inflammatory bowel disease, especially ulcerative colitis, it is decided to start intravenous corticosteroid

therapy: hydrocortisone 100 mg every 8 hours. After 2 weeks of evolution, the patient showed clinical improvement, decreased liquid stools and oral tolerance. Medical discharge with oral corticosteroids and azathioprine is indicated. Patient returned after 7 days due to increased frequency of liquid stools and



disorder of consciousness, entering the trauma shock unit with blood pressure: 70/40, heart rate: 140 beats per minute, ST02: 95%. She is stabilized, evaluated by gastroenterology, who requests toxin dosage for

Clostridium difficile, stool culture and, depending on the evolution, the possibility of video colonoscopy. Table 2 details the laboratory tests.

Table 2. Laboratory follow-up within 9 days of readmission.

Laboratory Exams	Day 1	Day 5	Day 7	Day 9
Leukocytes	24380	8310	19600	23710
Hb	12.1	9.7	12	11.6
Hematocrit	36	29	36	35
Platelets	346000	263000	272000	48000
Based	1 %	0	8 %	9 %
Segmented	96 %	85 %	70 %	71 %
Lymphocytes	2 %	11 %	11 %	6 %
Pt/ Inr		13.2	21.9	34.6
Aptt		0.98	1.69	2.77
Sodium		145	137	138
Potassium		2.06	4.69	4.19
Chlorine		103	104	100
Urea		17	73	91
Creatinine		0.26	1.26	1.37
Crp	41.4	1.79 /VSG: 26	27.99	15.6
Procalcitonin			92.6	25.88
Albumin		2.4	1.5	
Total Bilirubin		0.26	0.17	0.87
Direct Bilirubin		0.12	0.12	0.69
Tgo		14	20	389
Tgp		7	11	78
Fa		90	61	447
Ggtp		30	12	27

CLINICAL CASE

Stable patient with evident clinical improvement. A complete colonoscopy is performed where all segments of the colon are visualized: mucosa with erythema and areas of slight friability, preserved vascular pattern, dilation of the lumen and decrease in haustra, colonic decompression is performed and a biopsy is taken of all segments. Rectum: slightly friable erythematous congestive mucosa with erosions,

biopsies are taken. The procedure ends without complications. Colonoscopy (Figure 2) showed pancolitis and proctitis suggestive of ulcerative colitis, as well as small external hemorrhoids. Regarding the biopsy, the report indicated moderate non-active chronic colitis, absence of intraepithelial lymphocytes and presence of lymphoid accumulations in the lamina propria without alteration in the colonic architecture

and a mild non-active chronic proctitis. After analyzing the results of the auxiliary examinations, the definitive

diagnosis of ulcerative colitis causing toxic megacolon was made.

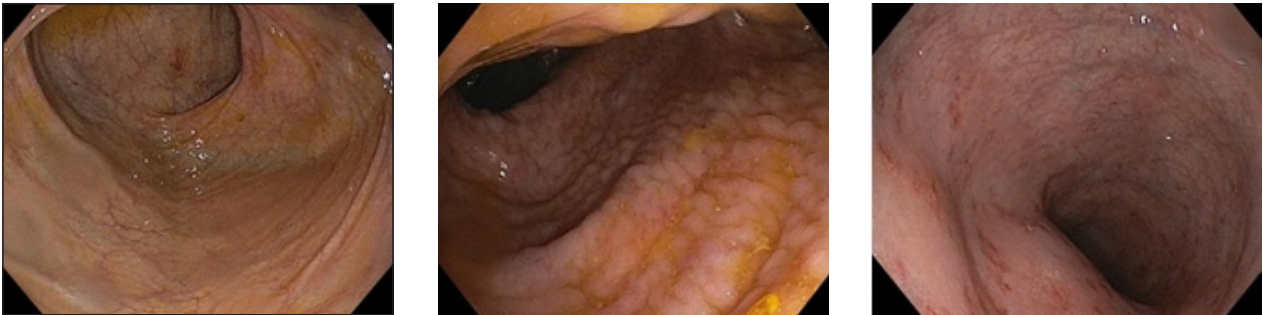

Figure 2a. Transverse colon. b.- sigmoid colon. C.- Rectum

Pathological anatomy result: Non-active moderate degree chronic colitis, absence of intraepithelial lymphocytes, presence of lymphoid accumulations in

the lamina propria, no architectural alteration is observed. Chronic proctitis, mild non-active degree (Figure 3).

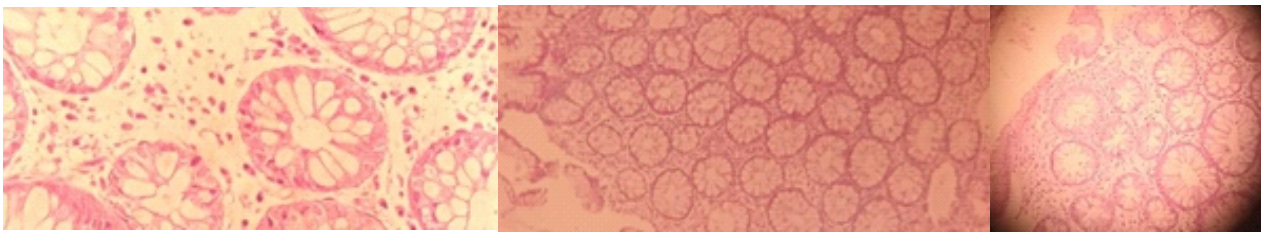


Figure 3. Pathology images

Clostridium difficile toxin result was positive, vancomycin + metronidazole was indicated, intravenously, monitored in the intensive care unit. The patient had an unfavorable evolution and died from septic shock on the 9th day of hospitalization.

DISCUSSION

Toxic megacolon is a potentially fatal disease, it occurs as a complication of inflammatory bowel disease, specifically ulcerative colitis and, less frequently CD^(5,9). However, there are other etiological factors of both inflammatory and infectious causes; such as bacterial colitis due to *C. difficile*, *Salmonella*⁽¹⁰⁾, *Shigella*⁽¹¹⁾ and *Campylobacter*⁽¹²⁾ as well as viral infections due to cytomegalovirus and parasitic infections due to

Entamoeba. Other etiological factors include ischemic colitis, Behçet's disease, and malignant diseases such as colon lymphoma and Kaposi's sarcoma. In a recent retrospective study by Ausch et al, over a 20-year period, 70 patients with surgically treated toxic megacolon were identified, of which ulcerative colitis was identified as the main cause of disease (46%), followed by colitis. infectious (34%) and ischemic colitis (11%); One case (2%) of toxic megacolon complicating CD was documented⁽¹³⁾.

According to Magallanes et al, in their retrospective observational study, ulcerative colitis and pseudomembranous colitis were presented as the cause in 30.8% each, followed by neutropenic colitis in 23.1% and Crohn's disease represented only 7.7%⁽¹⁵⁾



Our patient had endoscopic and laboratory criteria corresponding to ulcerative colitis that was complicated by toxic megacolon due to clostridium difficile infection.

Among the risk factors that increase mortality according to the study by Greenstein et al⁽¹⁴⁾, are female sex, age over 40 years, hypoalbuminemia, acidosis and high blood urea nitrogen levels, like Doshi et al⁽⁴⁾ where agrees that female sex, white race, average age of 60 years, coagulopathy, iron deficiency anemia and renal failure are strong predictors of in-hospital mortality. All of the aforementioned risk factors were present in the patient, such as age over 40 years, female sex, hypoalbuminemia and acidosis, which caused a torpid evolution.

The clinical characteristics of toxic megacolon are intense bloody diarrhea associated with hypotension, tachycardia, fever, diffuse abdominal pain with distention, and decreased bowel sounds⁽⁷⁾.

The presented case met the following diagnostic criteria for TM include (a) radiographic evidence of colonic dilation of more than 6 cm, especially in the transverse colon; (b) three of the following: fever (> 38.6 °C), tachycardia (> 120 beats/min), leukocytosis (> 10.5 × 10³/μl), or anemia; and (c) any of the following: hypotension, hypovolemia, altered mental status, or electrolyte disorders.⁷ Abdominal X-ray images allow evaluation of colonic dilation plus 6cm of the transverse colon, air-fluid levels, absent/distorted colonic haustral pattern. Contrast-enhanced computed tomography evaluates the extent of involvement (submucosal edema of the colon, pseudopolyps, haustral pattern, dilation), adjacent inflammation (mesenteric fat), and other associated features (ascites, abscesses, small bowel involvement) that is, it can better identify complications of toxic megacolon and facilitate subsequent treatment, there are no specific characteristics that suggest the underlying cause⁽⁸⁾.

An endoscopic study has a high risk, especially if a complete colonoscopy is to be performed, because it can cause perforation of the colon. If the cause is not clear, proctoscopy or sigmoidoscopy can be performed without bowel preparation, it is safer compared to complete colonoscopy. It is useful to diagnose inflammatory bowel disease or infection. During the procedure, air should not be insufflated and as much air as possible should be aspirated to achieve temporary decompression. Only a few biopsies should be taken⁽⁴⁾.

The treatment of toxic megacolon is multidisciplinary, general measures include fluid replacement, correction of hydroelectrolyte imbalance, particularly hypokalemia, which aggravates colonic dysmotility, colonic decompression, administration of antibiotics decreases bacterial translocation, antibiotics should be included in against gram-negative intestinal germs, enterococci. Early enteral nutrition if the patient shows signs of clinical improvement to promote intestinal motility and treat the cause of toxic megacolon^(4,7,16).

Timely medical treatment reduces the need for surgical management by 50%; However, surgical intervention may be necessary in up to 80% of patients, mainly if the cause is secondary to C. difficile.¹⁶ It has been reported that patients who survive an episode of toxic megacolon, after responding to treatment doctor have a poor survival prognosis of six to twelve months; They may present recurrence in more than 18% and recurrence may require colectomy⁽¹⁷⁾. Indications for surgical management are progressive colonic dilation, peritonitis, perforation, bleeding or deterioration of clinical status or lack of response within 48-72 hours despite appropriate medical treatment. Subtotal colectomy, according to a series of studies, has a long-term success rate of 71.1%, while segmental resection has a 48.4% success rate^(4,18). In Magallon's observational study, they had 13 patients with toxic megacolon, of which 11 patients (84.6%) underwent subtotal colectomy with terminal ileostomy and mortality

was 61.5%, which corresponds to 8 of 13 patients⁽¹⁵⁾. In the case presented, it is important to emphasize that it is one of the first cases reported in our Institution, where the patient presented the clinical, laboratory and imaging characteristics of toxic megacolon with clinical evolution favorable to initial medical management and corticosteroids since ulcerative colitis was considered. As a cause, he is discharged and re-admitted in septic shock.

Taking into account the use of broad-spectrum antibiotics, it is decided to request studies for *Clostridium difficile*, which come back positive, he receives antibiotic treatment, however, he has an unfavorable clinical evolution. which does not allow

surgical management to be considered due to the patient's torpid evolution. During the patient's second hospitalization, the high mortality rate due to the recurrence of toxic megacolon was not considered, which could be considered indicative of surgical management.

CONCLUSIONS

Toxic megacolon is a disease with high mortality that is characterized by bloody diarrhea associated with abdominal distension, signs of systemic toxicity, and in imaging studies the characteristic feature is colonic dilation of more than 6 cm. It is important to diagnose in a timely manner and initiate medical treatment to reduce the morbidity and mortality of these patients.

Author contributions: The authors participated in the conceptualization, research, methodology, resources and writing of the original draft.

Financing: Self-financed.

conflicts of interest: The authors declare that they have no conflict of interest.

Received: November 14, 2023.

Approved: March 02, 2024.

Correspondence: Roger Antonio Sernaque Mecható.
Address: Av. Simón Bolívar, cuadra 8 s/n. Pueblo Libre.
Telephone: 998995740
Email: internistagg@gmail.com

REFERENCES

1. Marshak RHLJ, Lester-Friedmann AI. Megacolon, a complication of ulcerative colitis. *Gastroenterology* 1950;16:768-772
2. Jalan KN, Sircus W, Card WI, et al. Una experiencia de colitis ulcerosa. I. Dilatación tóxica en 55 casos. *Gastroenterología*. 1969;57:68–82.
3. Gan SI, Beck PL. "Una nueva mirada al megacolon tóxico: una actualización y revisión de la incidencia, etiología, patogénesis y tratamiento". *Soy J Gastroenterol*. 2003; 98: 2363-2371.
4. Leifeld, L., & Krus, W. (2012). Management des toxischen Megakolons. *Zeitschrift Für Gastroenterologie*, 50(03), 316–322. doi:10.1055/s-0031-1299079
5. Doshi R, Desai J, Shah Y, Decter D, Doshi S. Incidencia, características, resultados hospitalarios y predictores de mortalidad hospitalaria asociados con hospitalizaciones por megacolon tóxico en los Estados Unidos. *Pasante Emerg Med*. 2018; 13 (6): 881–887. doi:10.1007/s11739-018-1889-8
6. Jalan KN, Sircus W, Card WI, et al. Una experiencia de colitis ulcerosa. I. Dilatación tóxica en 55 casos. *Gastroenterología*. 1969;57 (1):68–82. doi:10.1016/S0016-5085(19)33962-9
7. Desai J, Elnaggar M, Hanfy AA, Doshi R. Toxic Megacolon: Background, Pathophysiology, Management Challenges and Solutions. *Clin Exp Gastroenterol*. 2020 May 19;13:203-210. doi:10.2147/CEG.S200760.
8. Ong SCL, Mohaidin N. Características de imagen del megacolon tóxico. *Informes de casos* 2018;2018:bcr-2018-227121.
9. Daniel M. Autenrieth, Daniel C. Baumgart, Megacolon tóxico, enfermedades inflamatorias del intestino, volumen 18, número 3, 1 de marzo de 2012, páginas 584–591, Disponible en: <https://doi.org/10.1002/ibd.21847>
10. Chaudhuri A, Bekdash licenciado en Letras. Megacolon tóxico por Salmonella: reporte de un caso y revisión de la literatura. *Enfermedad colorrectal int J*.2002;17:275–279.
11. Brodrick R, Sagar j. Megacolon tóxico por infección de Shigella sonnei de transmisión sexual. *Enfermedad colorrectal int J*. 2011.
12. Schneider A, Runzi METRO, Peitgen k, et al. Colitis grave inducida por *Campylobacter jejuni*, una causa poco común de megacolon tóxico. *gastroenterol*.2000;38:307–309.



13. Ausch C, Madoff RD, Mosquito METRO, et al. Etiología y manejo quirúrgico del megacolon tóxico. *Enfermedad colorrectal*. 2006;8:195-201.
14. Greenstein AJ, Sachar DB, Gibas A, et al. "Resultado de la dilatación tóxica en la colitis ulcerosa y de Crohn". *J Clin Gastroenterol*. 1985; 7 (2): 137-143. doi: [10.1097/00004836-198504000-00007](https://doi.org/10.1097/00004836-198504000-00007)
15. Magallón-Tapia M, Cenicerós R. A, Arenas-Osuna J, Juárez-Leal C. L., Peralta-Amaro AL. Frecuencia, evolución clínica y pronóstico del megacolon tóxico. *Revista Médica del Instituto Mexicano del Seguro Social* [Internet]. 2015;53(1):S88-S93. Disponible en: <https://www.redalyc.org/articulo.oa?id=457744941014>
16. Siado Guerrero, S. A., Jiménez Sánchez, H. C., & Martínez Montalvo, C. M. (2018). Megacolon Tóxico De Origen Idiopático: Reporte De Caso. *Revista Colombiana De Gastroenterología*, 33(2), 166-171. Disponible en: <https://doi.org/10.22516/25007440.256>
17. Halaweish I, Alam HB. Manejo quirúrgico de la colitis grave en la unidad de cuidados intensivos. *J Medicina de Cuidados Intensivos*. 2015;30(8):451-61. doi: [10.1177/0885066614534941](https://doi.org/10.1177/0885066614534941).
18. Narváez Álvarez, C. M., Suazo Suárez, L. F., Mera Morales, P.V., & Salazar Vásquez, N. M. (2021). Megacolon tóxico, diagnóstico y tratamiento. *RECIMUNDO*, 5(4), 152-162. Disponible en: [https://doi.org/10.26820/recimundo/5.\(4\).oct.2021.152-162](https://doi.org/10.26820/recimundo/5.(4).oct.2021.152-162)