



# EVOLUTION OF PHOTODYNAMIC THERAPY IN THE MANAGEMENT OF ACTINIC KERATOSIS: HOW EFFECTIVE AND SAFE IS IT ACCORDING TO CURRENT EVIDENCE?

EVOLUCIÓN DE LA TERAPIA FOTODINÁMICA EN EL MANEJO DE LA QUERATOSIS ACTÍNICA:  
¿QUÉ TAN EFECTIVA Y SEGURA ES SEGÚN LA EVIDENCIA ACTUAL?

Laura Valentina Vargas Monroy <sup>a</sup>, Andrés Felipe Londoño Serna <sup>b</sup>, Duvan Alejandro Grisales Cano <sup>c</sup>,  
Carlos Andrés Jaraba Herazo <sup>d</sup>, Ivan Andres Peña Chamorro <sup>e</sup>, Max Jesus Bustillo Orozco <sup>f</sup>,  
Zulmy Valeria Montenegro Salcedo <sup>g</sup>, Michael Ortega Sierra <sup>h</sup>

## ABSTRACT

**Introduction:** Actinic keratosis is a premalignant dermatological condition characterized by the potential to progress to squamous cell carcinoma. To date, there is no treatment with an adequate benefit-risk balance. Photodynamic therapy is proposed as one of the most effective therapeutic tools. However, there is still divergence regarding the quality of available evidence. The objective of this review is to analyze the most recent evidence on the therapeutic performance of photodynamic therapy in the management of actinic keratosis. A literature search was conducted in the PubMed, Scopus, and MEDLINE databases. Based on the most recent randomized controlled trial comparing, the use of dynamic phototherapy combined with aminolevulinic acid without incubation versus incubation for one hour; it was found that the intervention group had a higher percentage of lesion resolution compared to the control group (49.5% vs. 34.9%,  $p=0.002$ ), as well as less pain in the intervention group ( $p=0.03$ ). In addition, a similar trend was observed in other studies, suggesting that this therapy could be effective and beneficial in the management of actinic keratosis. Despite the limited and heterogeneous evidence regarding the use of dynamic phototherapy and its various combined regimens for the management of actinic keratosis, there is a clear trend towards potential benefits compared to other therapies.

**Keywords:** Phototherapy, actinic keratosis, therapeutics, safety, efficacy. (Source: MESH-NLM)

## RESUMEN

**Introducción:** La queratosis actínica consiste en una entidad patológica dermatológica premaligna, caracterizada por tener el potencial de progresar a carcinoma escamocelular. A la fecha, no existe un tratamiento con un adecuado balance beneficio-riesgo. La terapia fotodinámica se postula como una de las herramientas terapéuticas más eficaces. No obstante, aún existe divergencia en cuanto a la calidad de la evidencia disponible. El objetivo de esta revisión consiste en analizar la evidencia más reciente sobre la evolución del rendimiento terapéutico de la terapia fotodinámica en el manejo de la queratosis actínica. Se realizó una búsqueda bibliográfica en las bases de datos PubMed, Scopus, y MEDLINE. Con base en el ensayo controlado aleatorizado más reciente, donde compararon el uso de fototerapia dinámica combinado con ácido aminolevulínico sin incubación versus con incubación de una hora, se evidenció que el grupo intervención tuvo mayor porcentaje de resolución de lesiones comparado al grupo control (49,5 % versus 34,9 %,  $p=0,002$ ), así como menor dolor en el grupo intervención ( $p=0,03$ ); adicional a la tendencia similar en los otros estudios, se encuentra que esta terapia podría ser eficaz y beneficiosa en el manejo de la queratosis actínica. A pesar de que la evidencia sobre el uso de fototerapia dinámica y sus distintos esquemas combinados, para el manejo de la queratosis actínica es limitada y heterogénea, existe una marcada tendencia sobre un potencial beneficio, comparado a otras terapias.

**Palabras clave:** Fototerapia, queratosis actínica, terapéutica, seguridad, Eficacia. (Fuente: DeCS- BIREME)

<sup>a</sup> General Physician, Medical Department, Universidad Nacional de Colombia, Bogotá, Colombia.

<sup>b</sup> General Physician, Faculty of Medicine, Corporación Universitaria Remington, Medellín, Colombia.

<sup>c</sup> General Physician, Faculty of Medicine, Universidad Cooperativa de Colombia, Medellín, Colombia.

<sup>d</sup> General Physician, Faculty of Medicine, Universidad de Ciencias Aplicadas y Ambientales, Bogotá, Colombia.

<sup>e</sup> General Physician, Faculty of Medicine, Universidad de Cartagena, Cartagena, Colombia.

<sup>f</sup> General Physician, Faculty of Medicine, Universidad del Norte, Barranquilla, Colombia.

<sup>g</sup> General Physician, Medical Department, Universidad del Cauca, Popayá, Colombia.

<sup>h</sup> General Physician, Universidad Centroccidental Lisandro Alvarado - Hospital Central Antonio María Pineda, Barquisimeto, Venezuela.

Cite as: Vargas Monroy LV, Londoño Serna AF, Grisales Cano DA, Jaraba Herazo CA, Peña Chamorro IA, Bustillo Orozco MJ, Montenegro Salcedo ZV, Ortega Sierra M. Evolution of photodynamic therapy in the management of actinic keratosis: How effective and safe is it according to current evidence?. Rev Fac Med Hum. 2024;24(4):190-195. [doi 10.25176/RFMH.v24i4.6016](https://doi.org/10.25176/RFMH.v24i4.6016)

Journal home page: <http://revistas.urp.edu.pe/index.php/RFMH>

Article published by the Journal of the Faculty of Human Medicine of the Ricardo Palma University. It is an open access article, distributed under the terms of the Creative Commons License: Creative Commons Attribution 4.0 International, CC BY 4.0 (<https://creativecommons.org/licenses/by/4.0/>), which allows non-commercial use, distribution and reproduction in any medium, provided that the original work is duly cited. For commercial use, please contact [revista.medicina@urp.edu.pe](mailto:revista.medicina@urp.edu.pe)





## INTRODUCTION

Actinic keratosis is a premalignant dermatological condition characterized by its potential to progress to squamous cell carcinoma<sup>(1)</sup>. These lesions appear in areas with a significant history of sun exposure and can be mistaken for other commonly observed lesions caused by the same trigger factor<sup>(2,3)</sup>. To date, there is a significant and precise lack of data to describe its epidemiological behavior<sup>(1,4)</sup>. However, it is presumed to be more common than previously thought in coastal areas where operational and labor environments are linked to chronic sun exposure<sup>(5)</sup>.

Although its pathogenesis and physiopathology are not precisely known, ultraviolet exposure has been reported to induce changes in regulatory signaling pathways at the keratinocyte level in the epidermal layer, creating an oncogenic environment that stimulates replication, differentiation, and tumor migration<sup>(1,5)</sup>. Therefore, early detection and timely management are essential to prevent progression to carcinoma. To date, there is no treatment with an adequate benefit-risk balance, as therapies focused on the lesion or the lesion territory frequently cause discomfort and side effects that affect the quality of life or result in morbidity<sup>(1,3)</sup>. Photodynamic therapy is considered one of the most effective therapeutic tools, as it can act on lesions that are not visible during physical examination, generating reactive oxygen species that eliminate abnormal cells<sup>(6-8)</sup>. However, there is still divergence regarding the quality of the available evidence<sup>(9,10)</sup>, especially since very few studies have specifically attempted to answer the therapeutic efficacy of photodynamic therapy in actinic keratosis, despite advancements in certain technical aspects<sup>(4)</sup>.

Given the relevance of this topic, particularly the lack of Spanish-language evidence that synthesizes literature for the understanding and potential management of this disease, the objective of this review is to analyze the most recent evidence on the therapeutic efficacy of photodynamic therapy in the management of actinic keratosis.

## METHODS

A bibliographic search was designed and reproduced using the search terms photodynamic therapy and actinic keratosis, along with synonyms, which were combined with the operators AND and OR in the PubMed, Scopus, and MEDLINE databases. Any full-text article evaluating the efficacy and safety of photodynamic therapy in the management of actinic keratosis was included, prioritizing original studies, systematic reviews, and meta-analyses. Articles published up to 2023 were included. A total of five articles with potentially relevant clinical evidence were identified. Additionally, references were included for the discussion of basic theoretical aspects of the disease and future perspectives. The estimates and findings were expressed in their original measures, whether frequencies, percentages, confidence intervals (CI), mean differences (MD), relative risk (RR), odds ratios (OR), or hazard ratios (HR).

### Physiopathological and therapeutic aspects of actinic keratosis

As mentioned earlier, actinic keratosis is a neoplasm resulting from the abnormal proliferation of epidermal keratinocytes<sup>(11)</sup>. Actinic keratosis lesions can present progressively but slowly and are characterized by small erythematous papules, sometimes pigmented, in areas with greater sun exposure<sup>(1,12)</sup>. The surrounding skin often presents telangiectasias, skin discoloration, solar elastosis, and dermal atrophy. However, according to the natural history phases of the disease, these lesions can resolve spontaneously, persist benignly, or, in the worst-case scenario, progress to malignancy<sup>(13)</sup>.

Nevertheless, it has been described that in cases where spontaneous regression occurs, there may be reappearance later<sup>(14)</sup>. This behavior can be greatly influenced by some reported potential risk factors that may contribute to the persistence or progression of the lesions, such as advanced age (over 60-65 years), male sex, fair skin, immunosuppression, a history of actinic keratosis or skin cancer, and the main associated factor: chronic sun exposure, which is related to residing in a

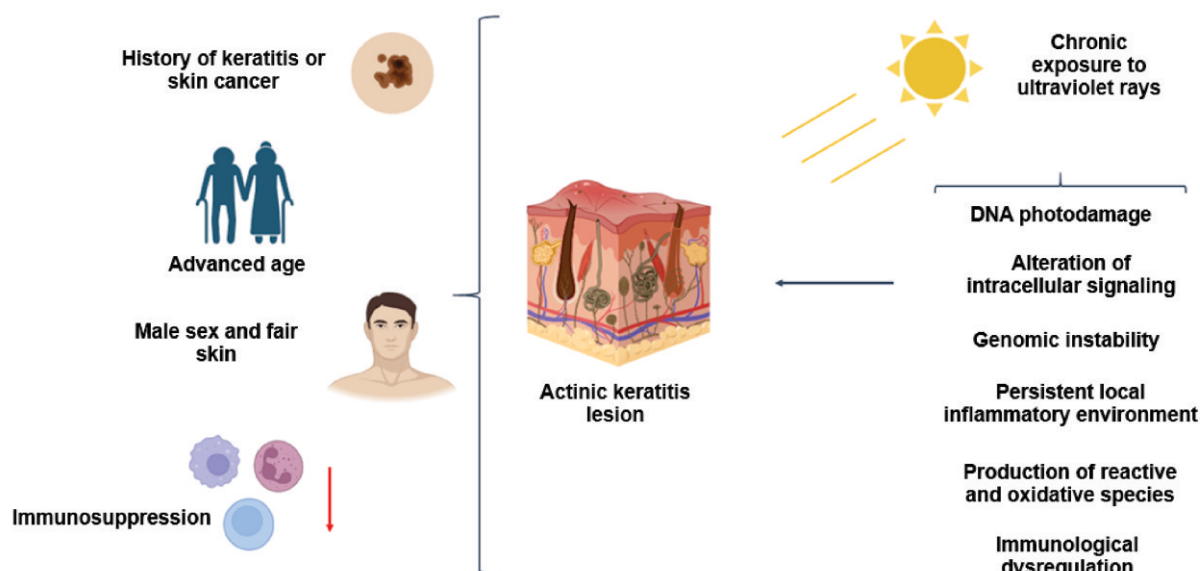




tropical region where higher temperatures are recorded compared to other areas with varied climates<sup>(14,15)</sup>. At the cellular and molecular levels, it has been proposed that, secondary to ultraviolet exposure, three mechanisms are triggered that can lead to genomic and cellular instability, resulting in the appearance of lesions and/or malignancy<sup>(16,17)</sup>.

Initially, ultraviolet rays cause photodamage to deoxyribonucleic acid (DNA), which, after significant exposure and alteration of cellular dynamics, leads to mutations in the p53 tumor suppressor gene and associated proteins, resulting in failure of the regulatory mechanisms of cell death, with consequent genomic

instability and abnormal replication and/or differentiation<sup>(3)</sup>. Additionally, ultraviolet rays, acting on the cellular phospholipid membrane, interact with arachidonic acid, leading to the release of prostaglandins through lytic processes, creating a chronic inflammatory environment<sup>(1)</sup>. Moreover, alterations in intracellular signaling have been described, due to the deregulation of reactive oxygen species metabolism, platelet-activating factor, and trans-urocanic acid, leading to cellular damage<sup>(3)</sup>. All of this produces a local immunological disorder that causes immunosuppression, which, combined with other physiopathological mechanisms, stimulates a pro-tumoral environment (Figure 1).



**Figure 1.** Cellular and molecular mechanisms and risk factors associated with the pathogenesis and pathophysiology of actinic keratosis. Source: Own elaboration.

Based on the information above, certain therapies have been proposed, such as cryotherapy, resection or excision, for the removal of lesions directly in the affected area<sup>(18-20)</sup>. Among the treatments applied directly to the site of the lesions, dermabrasion, laser, chemical peeling, photodynamic therapy, and topical medication (using 5-Fluorouracil, sodium diclofenac, or imiquimod) can be used. Of these, dynamic

phototherapy aims to apply a photosensitizer to a specific area, which, after controlled light exposure, generates reactive oxygen species that selectively destroy abnormal cells<sup>(1,19,20)</sup>. However, among the disadvantages described is pain production, which requires a prolonged waiting time in specialized centers. This is where the variation of daylight dynamic phototherapy comes into play.

This therapy has evolved in recent years for this condition<sup>(16,18,19)</sup>. However, how much evidence is there, and what is its quality?

### **Evolution of photodynamic therapy in the management of actinic keratosis: How effective and safe is it?**

Considering that the number of non-melanoma skin cancer cases has increased globally in recent years<sup>(21)</sup>, it is necessary to have high-quality clinical evidence applicable to real-world practice. In 2012, in a Cochrane review conducted by Gupta et al.<sup>(22)</sup>, evidence was systematized on interventions for actinic keratosis, including 83 randomized controlled trials with a sample of 10,036 subjects. Firstly, the authors highlighted a methodological deficit among the studies, with a high risk of reporting bias.

Secondly, regarding outcomes, in the case of lesion clearance, site-directed treatments: 3% diclofenac plus 2.5% hyaluronic acid (RR 2.46; 95% CI: 1.66 - 3.66), 0.5% 5-fluorouracil (RR 8.86; 95% CI: 3.67 - 21.44), 5% imiquimod (RR 7.70; 95% CI: 4.63 - 12.79), and 0.025%-0.05% ingenol mebutate (RR 4.50; 95% CI: 2.61 - 7.74) showed superiority compared to placebo. Regarding photodynamic therapy, it was evidenced that, in the case of individual lesion resolution, the combined use of aminolevulinic acid and methyl aminolevulinate as photosensitizers with phototherapy increased the likelihood of lesion resolution by 5.22 (95% CI: 2.88 - 13.43) and 3.56 (95% CI: 3.17 - 6.28) times. However, a significant number of patients (n=261/4000) experienced adverse effects, leading to withdrawal. Still, up to that point, phototherapy was concluded to be the most effective therapy in terms of resolution and cosmetic outcomes compared to other therapies<sup>(22)</sup>.

In 2021, Galitzer et al.<sup>(23)</sup> published the results of the first randomized study, which included 15 patients with actinic keratosis, aiming to determine the efficacy and safety of dynamic phototherapy. They used 10% levulinic acid gel, red light, and adapalene prior to treatment. The therapy was implemented as follows: the use of 0.1% adapalene gel twice daily for one week before dynamic phototherapy application.

The control group was exposed to dynamic phototherapy only. After eight weeks, it was found that 12 subjects in the intervention group achieved 50% to 100% lesion resolution, compared to 10 subjects in the control group. Additionally, the median lesion reduction time was 72% shorter compared to the control group (p=0.01); both groups had good tolerability, and patients reported high satisfaction. It was concluded that the proposed scheme was effective and safe for the management of actinic keratosis<sup>(23)</sup>.

A year later, Kiss et al.<sup>(24)</sup> shared the results of a case series composed of 10 patients who underwent a single session of photodynamic therapy combined with aminolevulinic acid. The researchers observed a complete response in three individuals and partial response in the rest. Overall, tolerability was good, with local adverse events reported in only four patients<sup>(24)</sup>. Recently, in 2023, Salman et al.<sup>(25)</sup> conducted the most up-to-date meta-analysis, evaluating the safety and efficacy of the combination of cryotherapy and dynamic phototherapy with imiquimod for actinic keratosis, including five studies. The global analysis showed that the combination of cryotherapy and imiquimod increased the probability of lesion resolution by up to 5.2 times (95% CI: 1.56 - 24.1; p=0.01), compared to other regimens. Additionally, combining imiquimod with photodynamic therapy increased lesion resolution by 5% compared to using either therapy alone<sup>(25)</sup>.

Up to this point, these regimens were considered the most effective therapies for managing actinic keratosis until Anvery et al.<sup>(10)</sup> published the results of a randomized controlled trial comparing the use of photodynamic therapy combined with aminolevulinic acid without incubation versus with one-hour incubation for actinic keratosis. The authors included 27 subjects (n=13 in the intervention group versus n=14 in the control group) and evaluated outcomes at one week and eight weeks. After follow-up, it was shown that the intervention group had a higher percentage of lesion resolution compared to the control group (49.5% versus 34.9%, p=0.002). Additionally, less pain was reported in the intervention



group ( $p=0.03$ ). However, there was no statistically significant difference in the average dermal irritation score, days to return to work, or patient satisfaction. Interestingly, 19 adverse events were reported in the intervention group, compared to 14 in the control group. Still, the authors concluded that the use of phototherapy with aminolevulinic acid without incubation could be more effective than therapy with incubation<sup>(10)</sup>.

This analysis shows an evolution from isolated photodynamic therapy to certain combinations, which demonstrate heterogeneous results. However, in addition to methodological limitations, the evidence is limited. Therefore, the synthesis of evidence should be analyzed and interpreted with caution, as the measurement and combination of therapies are highly divergent, and the results can be magnified.

#### Future perspectives

According to Cramer & Stockfleth<sup>(26)</sup>, actinic keratosis will become a more important pathological entity than currently thought, as climate and demographic transitions will increase sun exposure and the populations exposed, which could become the most frequent in situ skin carcinoma worldwide<sup>(26)</sup>. This should spark interest among researchers in skin cancer, not just dermatologists, but other health professionals and related individuals, to consider the clinical and translational evaluation of actinic keratosis<sup>(27,28)</sup>, where there is a significant lack of primary data, especially in Latin America and the Caribbean. Considering

genomic and genetic population variability, it is imperative to conduct studies taking into account variables specific to each sociodemographic and health context to contribute to the search for answers that allow the implementation of strategies based on precision medicine<sup>(29)</sup>. Current therapies are very diverse. It is worth noting that the study population has been very similar, which prevents attempts to extrapolate results to communities with different anthropological, social, and clinical characteristics, as the natural history of the disease is unknown in certain populations. Based on these results, it is even possible to design and implement health policies and plans to create or modify roadmaps for screening, diagnosis, and timely treatment. In low- and middle-income countries, such as those in Latin America and the Caribbean<sup>(30)</sup>, it is necessary to promote this type of research to contribute to achieving global health goals and the global cancer agenda, in addition to promoting the development of science and technology in skin cancer and topics of interest in technology.

#### CONCLUSIONS

Although the evidence on the use of dynamic phototherapy and its various combined regimens for the management of actinic keratosis is limited and heterogeneous, there is a trend toward a potential benefit compared to other therapies, mainly due to lesion resolution, favorable patient satisfaction, and low or no pain perception, with a good benefit-risk balance, given by few adverse events.

**Authorship contributions:** The authors participated in the conceptualization, research, methodology, resources, and writing of the original draft.

**Funding:** This article has been funded by the authors.

**Conflicts of interest:** The authors declare that they have no conflict of interest.

**Received:** October 25, 2024.

**Approved:** July 17, 2024.

**Correspondence:** Michael Ortega Sierra.

**Address:** Universidad Centroccidental Lisandro Alvarado - Hospital Central Antonio María Pineda, Barquisimeto, Venezuela.

**Email:** [mortegas2021@gmail.com](mailto:mortegas2021@gmail.com)

## REFERENCES

- Marques E, Chen TM. Actinic Keratosis. [Updated 2023 Aug 17]. In: StatPearls [Internet]. Treasure Island (FL): StatPearls Publishing; 2023 Jan-. Available from: <https://www.ncbi.nlm.nih.gov/books/NBK557401/>
- Del Regno L, Catapano S, Di Stefani A, Cappilli S, Peris K. A Review of Existing Therapies for Actinic Keratosis: Current Status and Future Directions. *Am J Clin Dermatol*. 2022;23(3):339-352. doi:10.1007/s40257-022-00674-3
- Reinehr CPH, Bakos RM. Actinic keratoses: review of clinical, dermoscopic, and therapeutic aspects. *An Bras Dermatol*. 2019;94(6):637-657. doi:10.1016/j.abd.2019.10.004
- Siegel JA, Korgavkar K, Weinstock MA. Current perspective on actinic keratosis: a review. *Br J Dermatol*. 2017;177(2):350-358. doi:10.1111/bjd.14852
- Han H, Berman B. Clinical Management of Actinic Keratosis: Review and Update. *SKIN The Journal of Cutaneous Medicine*. 2022;6(4):274-285. doi:10.25251/skin.6.4.1
- Mosaddad SA, Mahootchi P, Rastegar Z, Abbasi B, Alam M, Abbasi K, et al. Photodynamic Therapy in Oral Cancer: A Narrative Review. *Photobiomodul Photomed Laser Surg*. 2023;41(6):248-264. doi:10.1089/photob.2023.0030
- Osuchowski M, Bartusik-Aebisher D, Osuchowski F, Aebisher D. Photodynamic therapy for prostate cancer - A narrative review. *Photodiagnosis Photodyn Ther*. 2021;33:102158. doi:10.1016/j.pdpdt.2020.102158
- Fayter D, Corbett M, Heirs M, Fox D, Eastwood A. A systematic review of photodynamic therapy in the treatment of pre-cancerous skin conditions, Barrett's oesophagus and cancers of the biliary tract, brain, head and neck, lung, oesophagus and skin. *Health Technol Assess*. 2010;14(37):1-288. doi:10.3310/hta14370
- Mpourazanis G, Kenschake W, Vogiatzis R, Papalexis P, Georgakopoulou VE, Ntritsos G, et al. The Role and Effectiveness of Photodynamic Therapy on Patients With Actinic Keratosis: A Systematic Review and Meta-Analysis. *Cureus*. 2022;14(6):e26390. doi:10.7759/cureus.26390
- Anvery N, Christensen RE, Dirr MA, Yi MD, Johnson T, Weil A, et al. Comparative effectiveness of 5-aminolevulinic acid photodynamic therapy with no incubation versus one-hour incubation for the treatment of actinic keratosis: A randomized controlled trial. *J Am Acad Dermatol*. 2023;89(2):401-403. doi:10.1016/j.jaad.2023.03.056
- Rosen T, Lebwohl MG. Prevalence and awareness of actinic keratosis: barriers and opportunities. *J Am Acad Dermatol*. 2013;68(1 Suppl 1):S2-9. doi:10.1016/j.jaad.2012.09.052
- Lampléy N, Rigo R, Schlesinger T, Rossi AM. Field Therapy for Actinic Keratosis: A Structured Review of the Literature on Efficacy, Cost, and Adherence. *Dermatol Surg*. 2023;49(2):124-129. doi:10.1097/DSS.0000000000003677
- Wenande E, Togsverd-Bo K, Hastrup A, Lei U, Philipsen PA, Haedersdal M. Skin Cancer Development Is Strongly Associated with Actinic Keratosis in Solid Organ Transplant Recipients: A Danish Cohort Study. *Dermatology*. 2023;239(3):393-402. doi:10.1159/000529369
- Li Y, Wang J, Xiao W, Liu J, Zha X. Risk Factors for Actinic Keratoses: A Systematic Review and Meta-Analysis. *Indian J Dermatol*. 2022;67(1):92. doi:10.4103/ijid.859\_21
- Hashim PW, Chen T, Rigel D, Bhatia N, Kircik LH. Actinic Keratosis: Current Therapies and Insights Into New Treatments. *J Drugs Dermatol*. 2019;18(5):s161-166.
- Nguyen M, Sandhu SS, Sivamani RK. Clinical utility of daylight photodynamic therapy in the treatment of actinic keratosis - a review of the literature. *Clin Cosmet Investig Dermatol*. 2019;12:427-435. doi:10.2147/CCID.S16749
- de Oliveira ECV, da Motta VRV, Pantoja PC, Ilha CSO, Magalhães RF, Galadari H, et al. Actinic keratosis - review for clinical practice. *Int J Dermatol*. 2019;58(4):400-407. doi:10.1111/ijd.14147
- Sinclair R, Baker C, Spelman L, Supranowicz M, MacMahon B. A review of actinic keratosis, skin field cancerisation and the efficacy of topical therapies. *Australas J Dermatol*. 2021;62(2):119-123. doi:10.1111/ajd.13447
- Arcuri D, Ramchatesingh B, Lagacé F, Iannatone L, Netchiporouk E, Lefrançois P, et al. Pharmacological Agents Used in the Prevention and Treatment of Actinic Keratosis: A Review. *Int J Mol Sci*. 2023;24(5):4989. <https://doi.org/10.3390/ijms24054989>
- Steeb T, Petzold A, Hornung A, Wessely A, Berking C, Heppt MV. Spontaneous regression rates of actinic keratosis: a systematic review and pooled analysis of randomized controlled trials. *Sci Rep*. 2022;12(1):5884. doi:10.1038/s41598-022-09722-8
- Ericson MB, Wennberg AM, Larkö O. Review of photodynamic therapy in actinic keratosis and basal cell carcinoma. *Ther Clin Risk Manag*. 2008;4(1):1-9.
- Gupta AK, Paquet M, Villanueva E, Brintnell W. Interventions for actinic keratoses. *Cochrane Database Syst Rev*. 2012 Dec 12;12(12):CD004415. <https://doi.org/10.1002/14651858.CD004415.pub2>
- Galitzer BI. Photodynamic Therapy for Actinic Keratoses of the Upper Extremities using 10% Aminolevulinic Acid Gel, Red Light, and Adapalene Pretreatment. *J Clin Aesthet Dermatol*. 2021;14(10):19-24.
- Kiss N, Farkas K, Tosti G, De Gado F, Bergler-Czop B, Fazio G, et al. Photodynamic Therapy with 5-Aminolevulinic Acid Patch for the Treatment of Actinic Keratosis. *J Clin Med*. 2022;11(11):3164. doi:10.3390/jcm11113164
- Salman S, Sarsik SM, El-Qushayri AE, Sakr S, Ghozy S, Salem ML. Safety and efficacy of the combination of cryotherapy and photodynamic modalities with imiquimod in patients with actinic keratosis: a systematic review and meta-analysis. *Ital J Dermatol Venerol*. 2023;158(1):15-20. doi:10.23736/S2784-8671.22.07461-8
- Cramer P, Stockfleth E. Actinic keratosis: where do we stand and where is the future going to take us? *Expert Opin Emerg Drugs*. 2020;25(1):49-58. <https://doi.org/10.1080/14728214.2020.173081>
- Dianzani C, Conforti C, Giuffrida R, Corneli P, di Meo N, Farinazzo E, et al. Current therapies for actinic keratosis. *Int J Dermatol*. 2020;59(6):677-684. doi:10.1111/ijd.14767
- Kircik LH. Addressing the Challenges of Treating Actinic Keratosis. *J Drugs Dermatol*. 2019;18(5):s160.
- Lozada-Martinez ID, Suarez-Causado A, Solana-Tinoco JB. Ethnicity, genetic variants, risk factors and cholelithiasis: The need for eco-epidemiological studies and genomic analysis in Latin American surgery. *Int J Surg*. 2022;99:106589. doi:10.1016/j.ijsu.2022.106589
- Pérez-Fontalvo NM, De Arco-Aragón MA, Jiménez-García JDC, Lozada-Martinez ID. Molecular and computational research in low- and middle-income countries: Development is close at hand. *J Taibah Univ Med Sci*. 2021;16(6):948-949. doi:10.1016/j.jtumed.2021.06.010